

Τι είναι το OCT;

Διαγνωστική τεχνική απεικόνισης που εξετάζει τον ζωντανό ιστό μη επεμβατικά. Βασίζεται σε μια σύνθετη ανάλυση της αντανάκλασης της ακτινοβολίας χαμηλής συνοχής από τον υπό εξέταση ιστό.

HISTORY OF OCT

- 1991 - first OCT paper - by Huang et al
- First in-vivo studies of human retina - 1993

Academia

Start-up

Carl Zeiss

Outlook

1990
Pre-Basic
research

1991
Patent
application

1995
Early
prototype

1996
OCT1
(Lab tool)

1997
OCT1

2000
OCT2
(Upgraded)

2002
Stratus
OCT

2007
Cirrus
HD-OCT


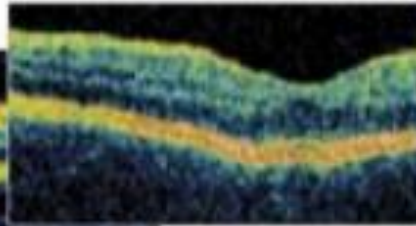
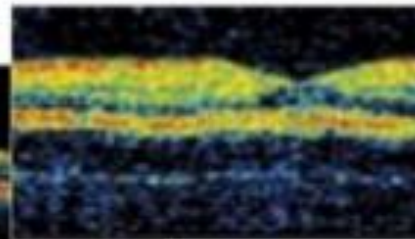
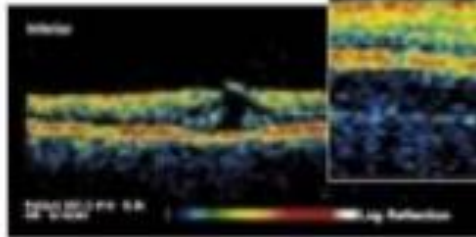
1st generation



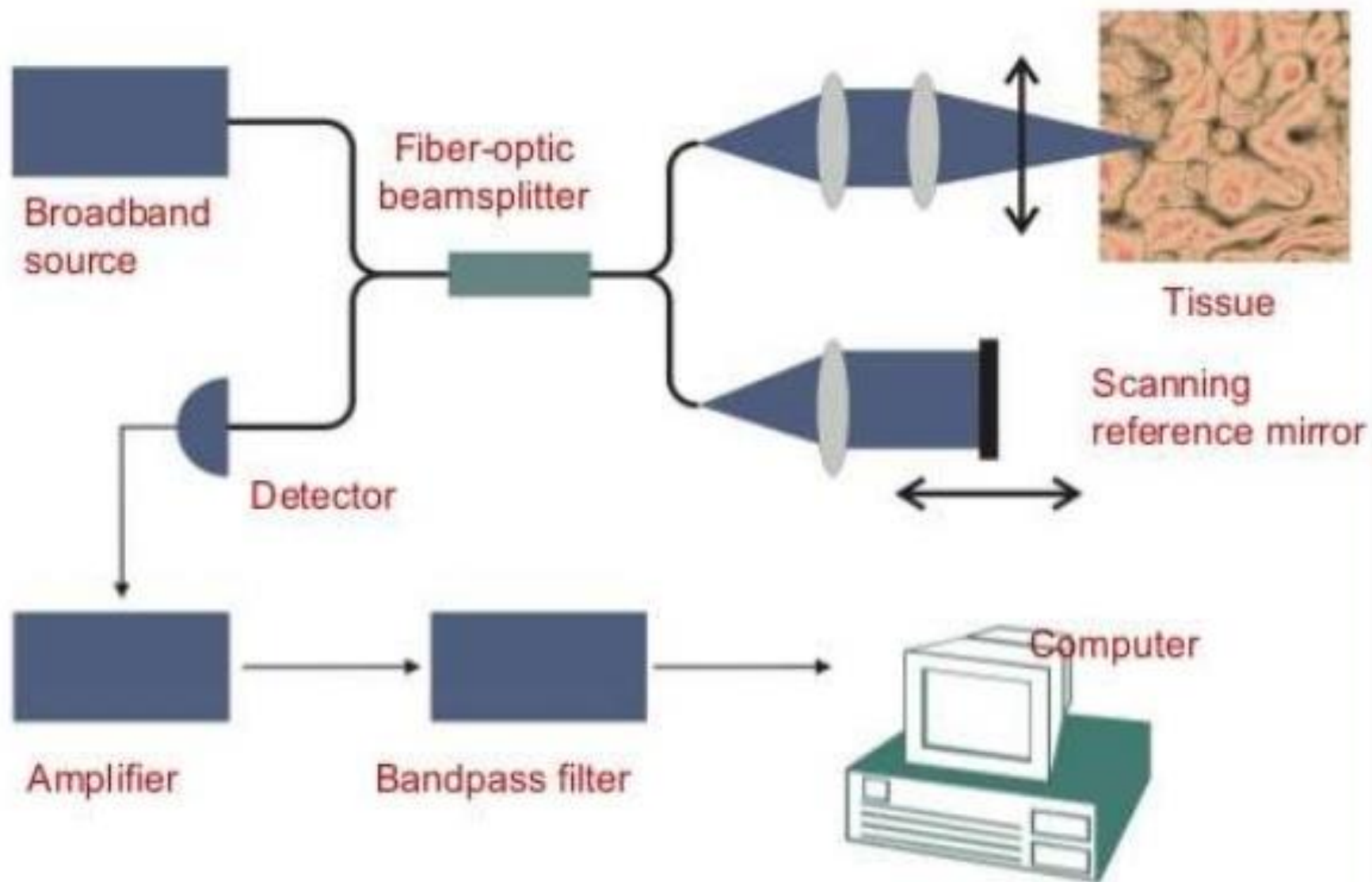
2nd generation



3rd generation



THE OCT SETUP

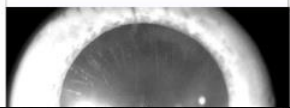
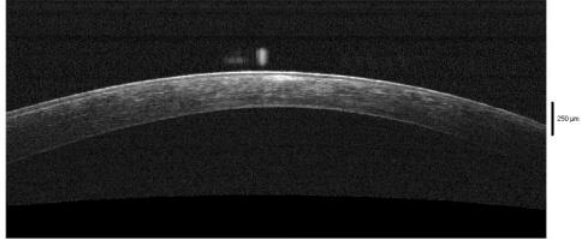


- OCT προσθίου ημιμορίου (κερατοειδής, πρόσθιος θάλαμος, κρυσταλλοειδής φακός)
- OCT οπίσθιου οφθαλμού (ωχρά κηλίδα, οπτικό νεύρο)

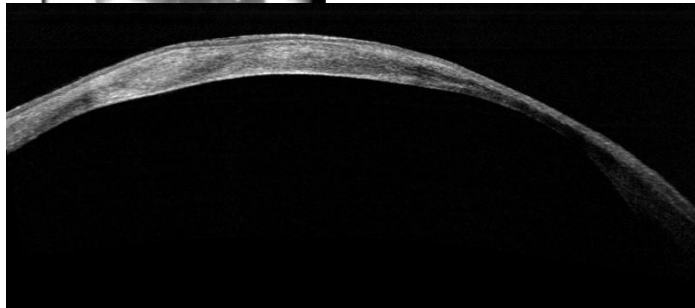
Optical Coherence Tomography (OCT) κερατοειδούς

Patient: 110001990 (27)
DOB (yy-mm-dd): 11/06/1990 (27)
Sex: M
CL - Line: SSI= 40.0
6.00mm ScanLength

Operator: 110001990 (27)
Exam Date: 09/28/2010
Physician:

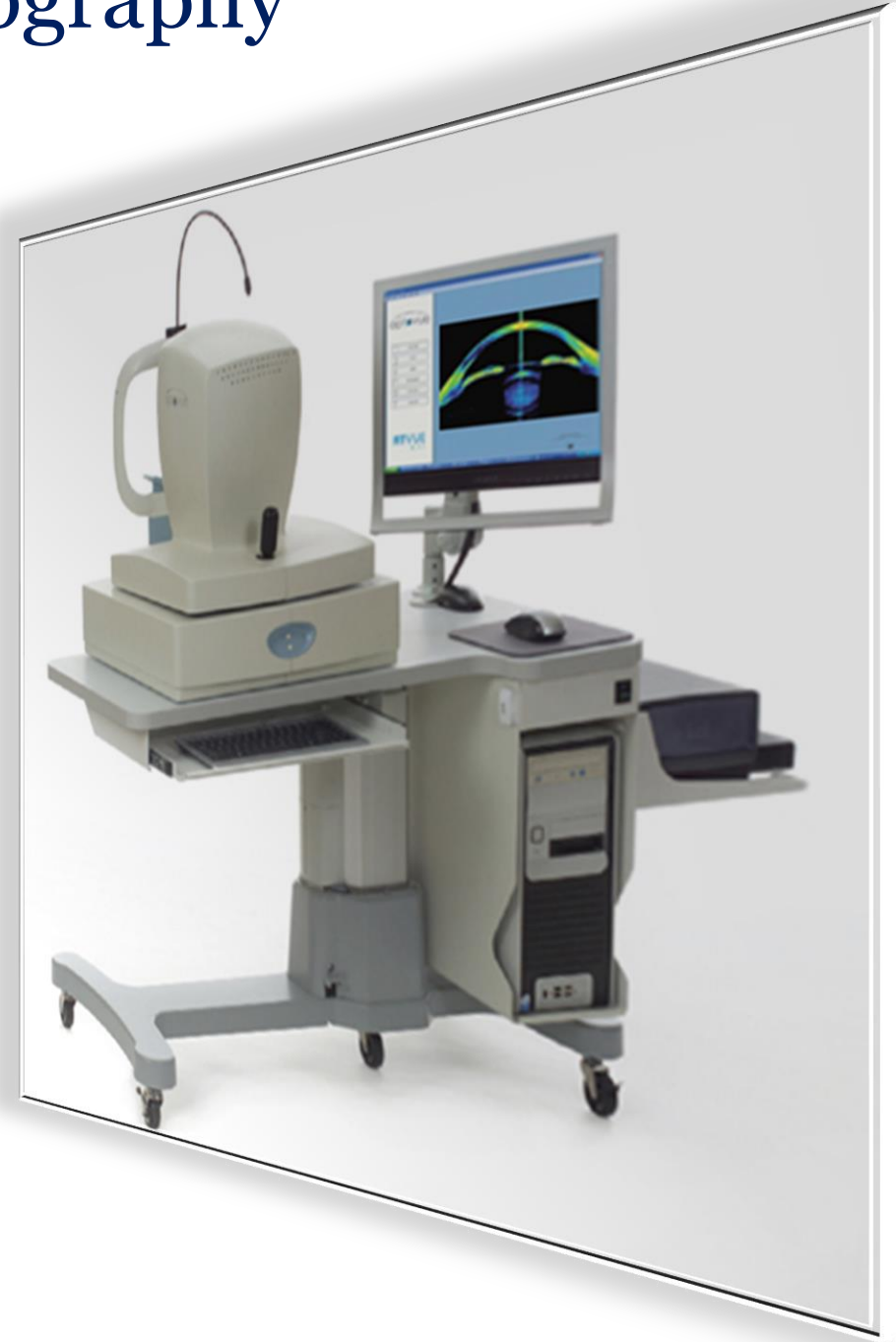

of Averages: 7
Average
No Average



Δυνατότητα λήψεων
τομών του κερατοειδή
με κατευθυνόμενη
διεύθυνση

Παχυμετρία

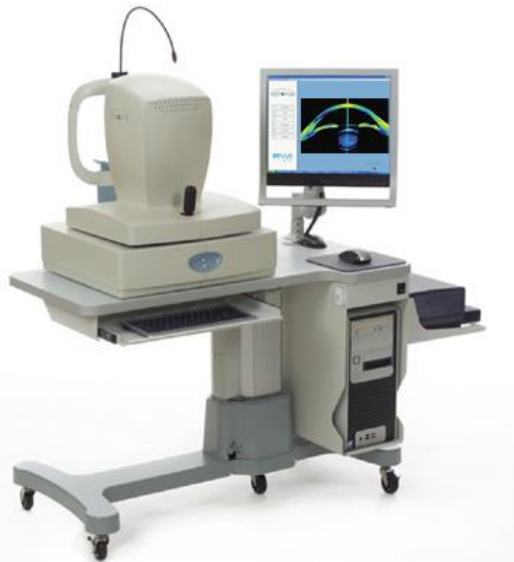

Epithelial Imaging

8 meridians

8 x 1019 A scans

0.31 sec acquisition time



Patient:
DOB (age): 10/05/1987 (25)
ID:

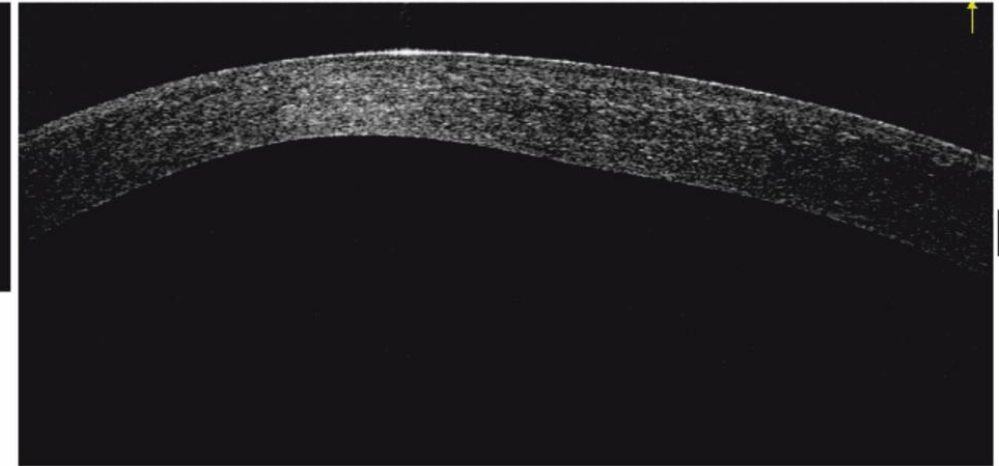
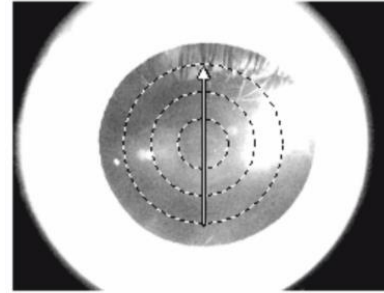
Disease:
Algorithm Version: A6, 9, 0, 27
Gender: M

Operator:
Exam Date: 11/19/2012
Physician:

OS

Pachymetry

SSI = 32.7



Pachymetry

Pachymetry statistics within central 5mm zone

SN-IT(2-5mm): 126 S-I(2-5mm): 124

Min: 453 Location Y: -1438

Min-Median: -104 Min-Max: -167

Min thickness at(0.530mm, -1.438mm) indicated as *

Epithelium

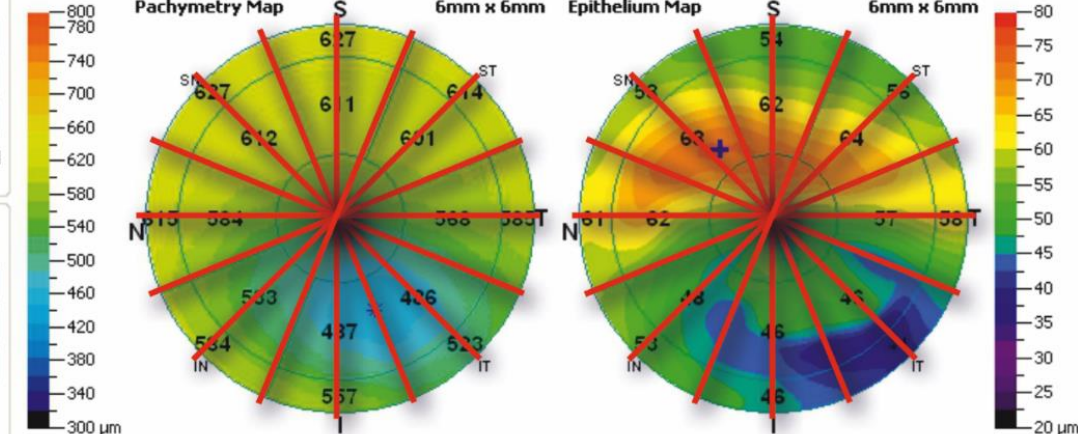
Epithelium statistics within central 5mm zone

Superior: 65 Inferior: 49

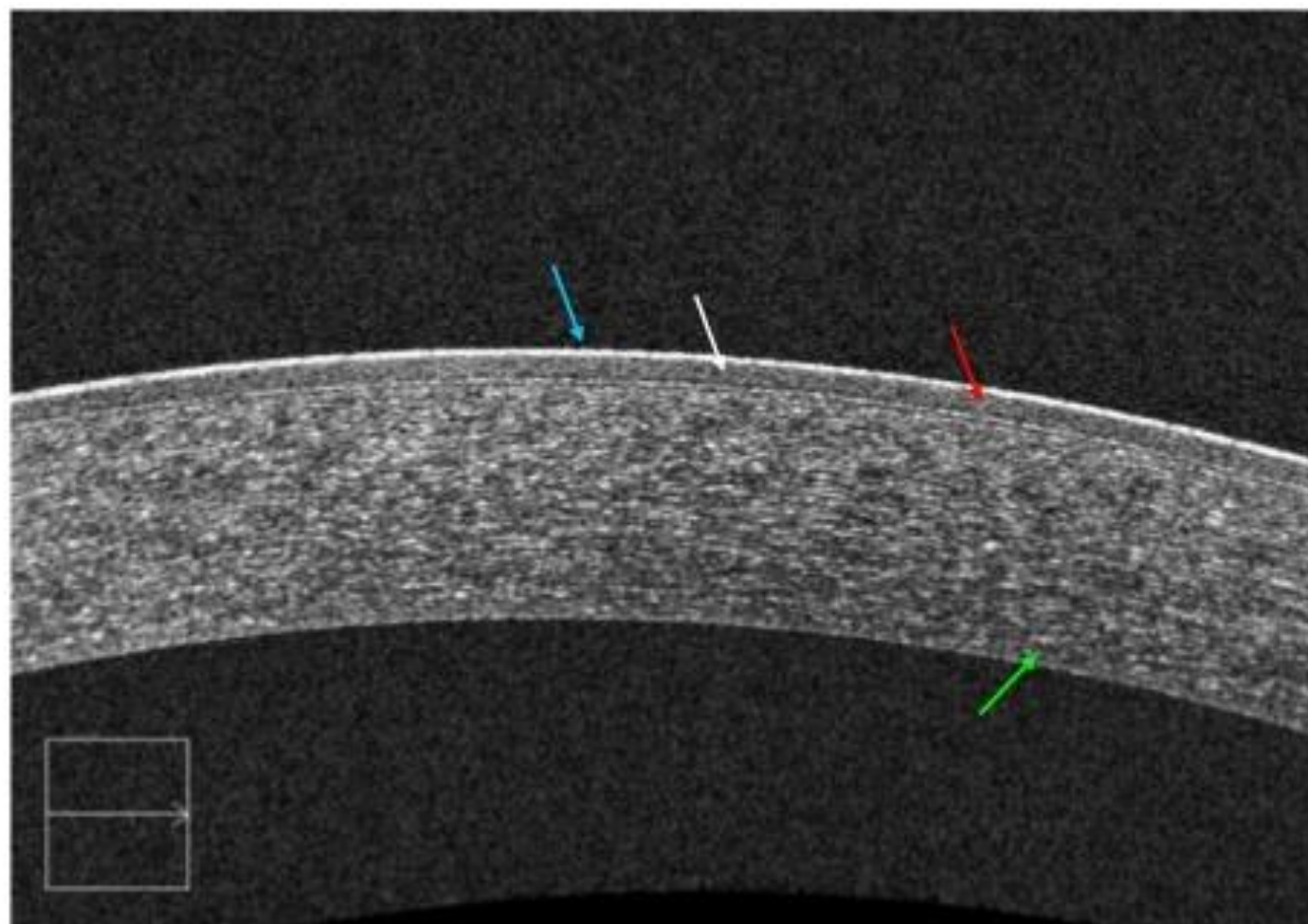
Min: 38 Max: 73

Std Dev: 9.3 Min-Max: -34

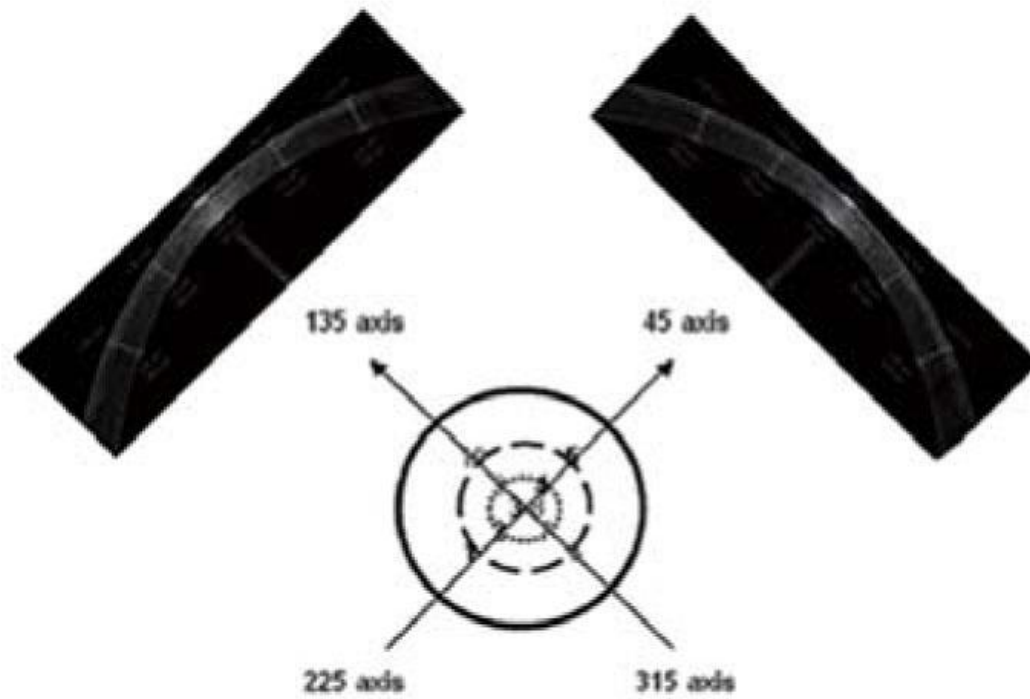
Min/Max thickness indicated as */+



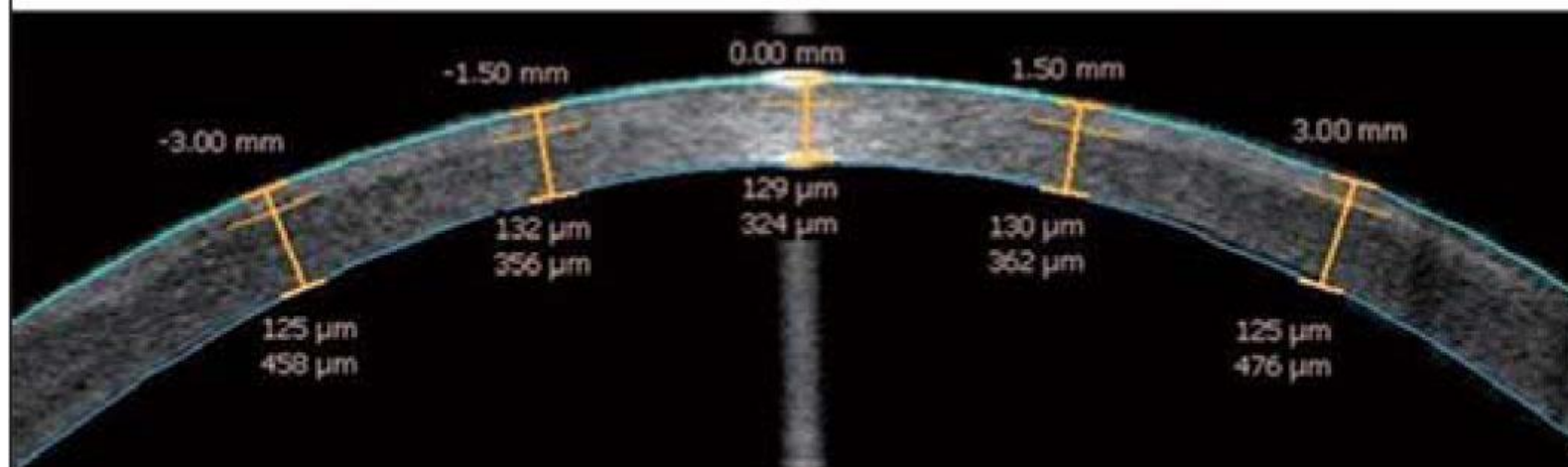
Diagnosis:

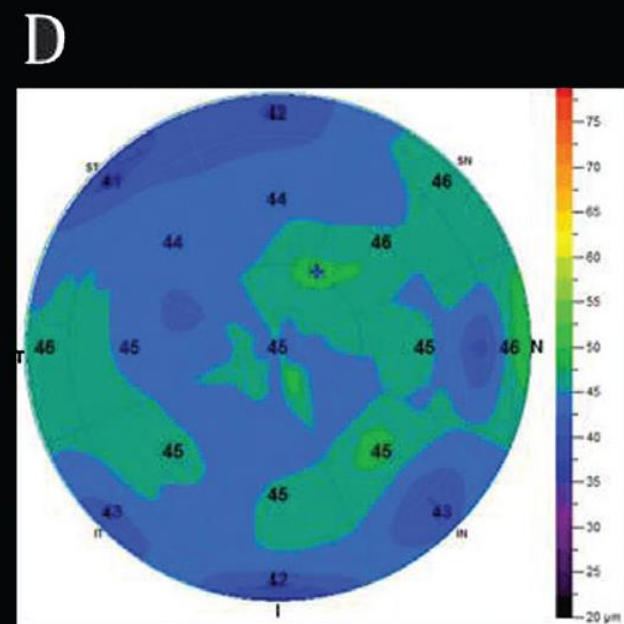
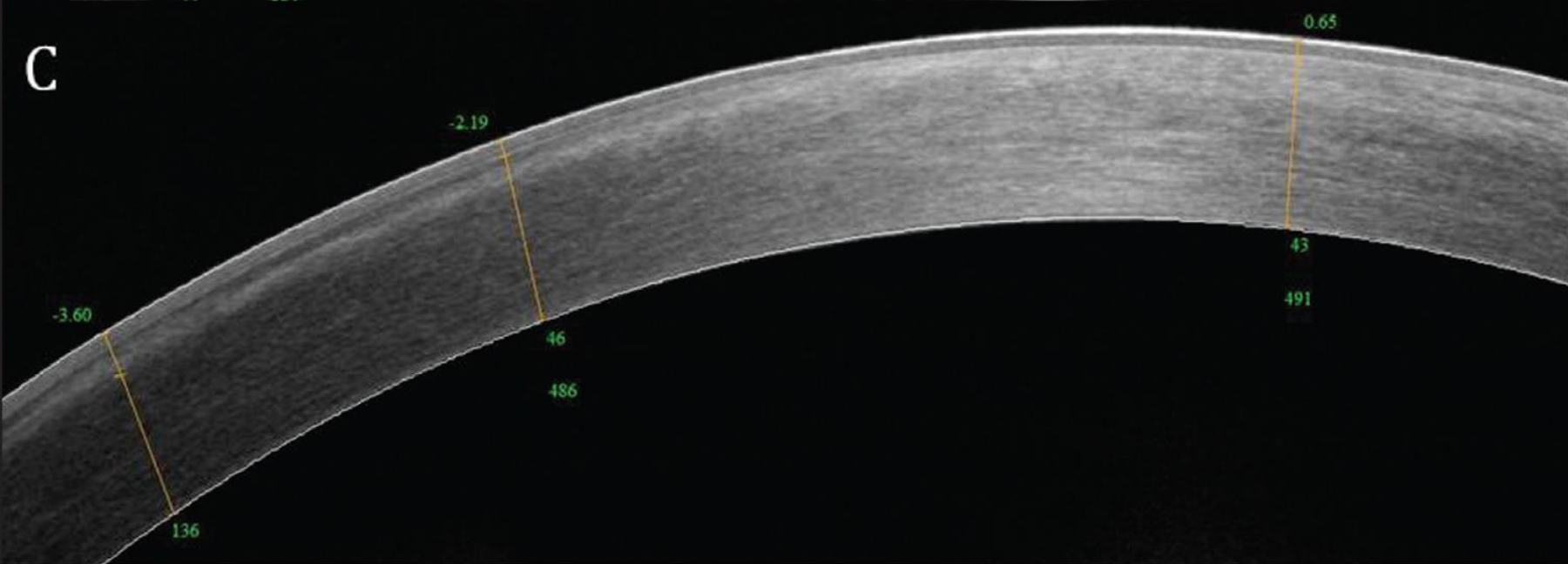
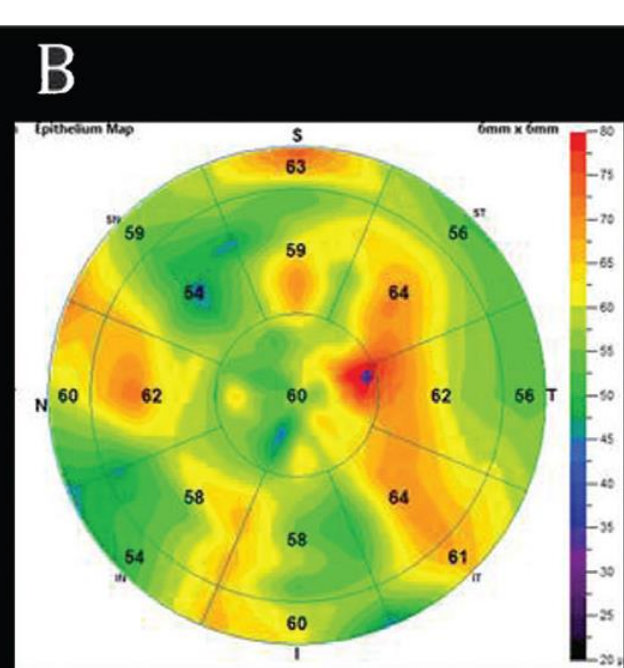
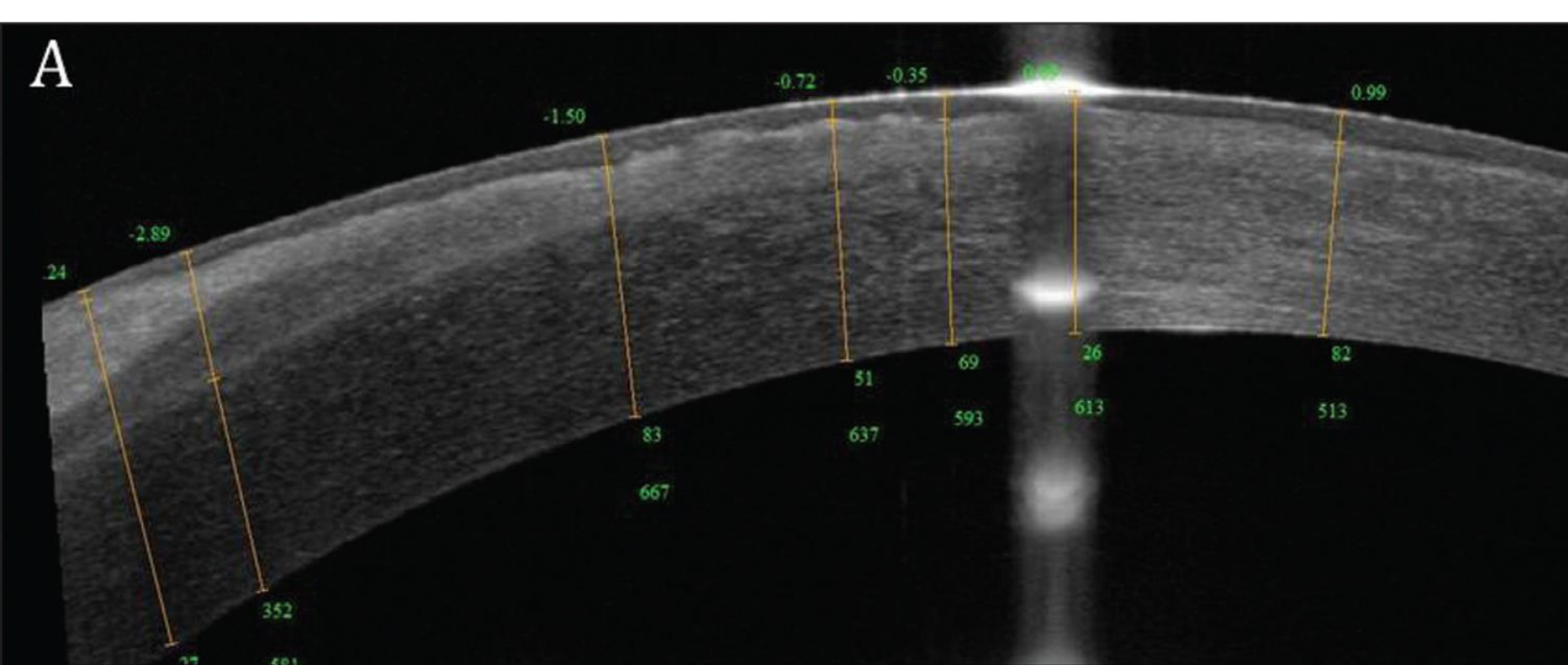


Cirrus HD-OCT scan of normal cornea. Layers identified with colored arrows as follows: tear film (blue), epithelium (white), Bowman's layer (red), Descemet's/endothelium (green).



10 measurement points(1~10)





Φυσιολογικός κερατοειδής

Pachymetry

Pachymetry statistics within central 5mm zone

SN-IT(2-5mm): S-I(2-5mm):

Min: Location Y:

Min-Median: Min-Max:

Min thickness at(0.330mm, -0.088mm) indicated as *

Epithelium

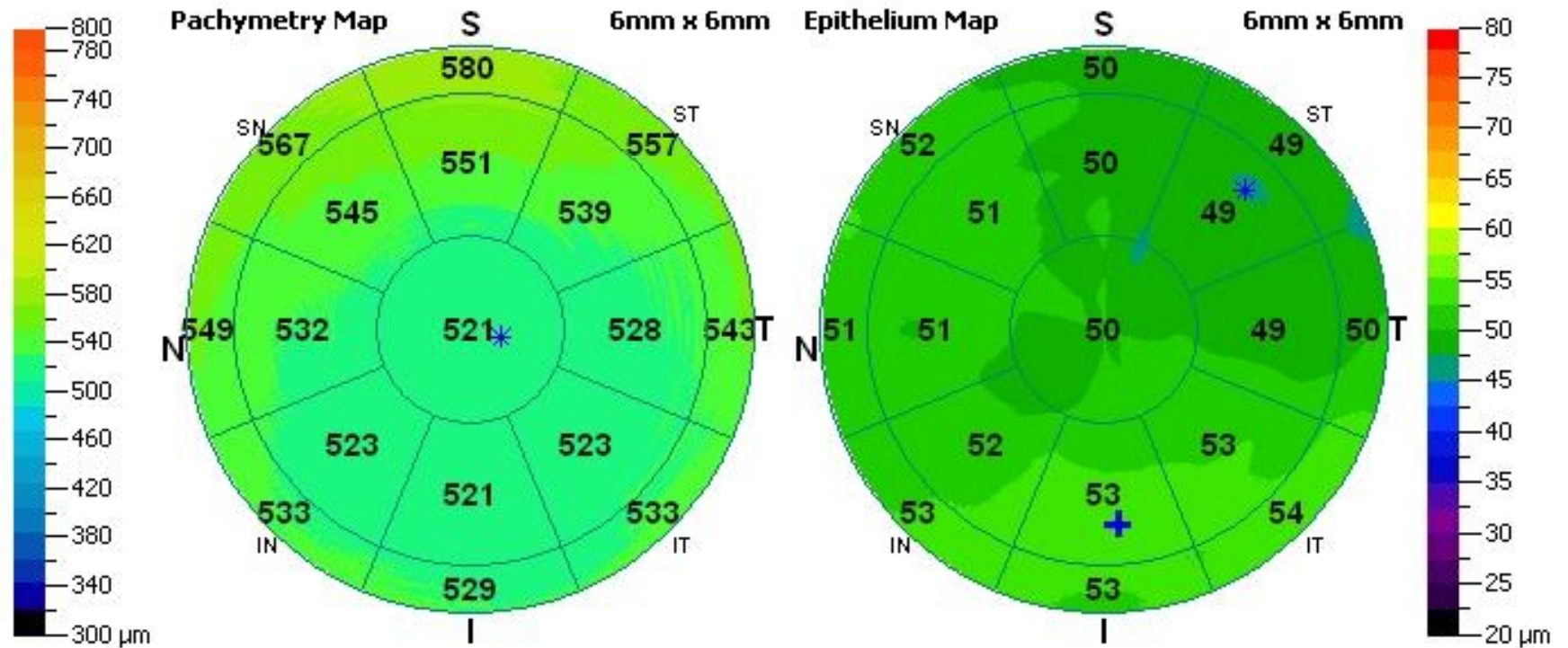
Epithelium statistics within central 5mm zone

Superior: Inferior:

Min: Max:

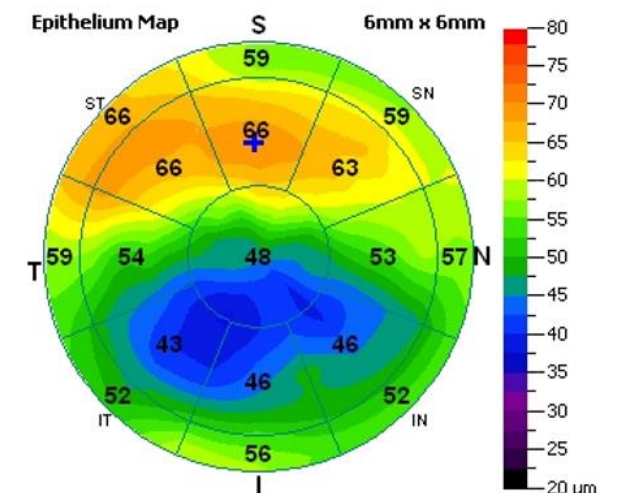
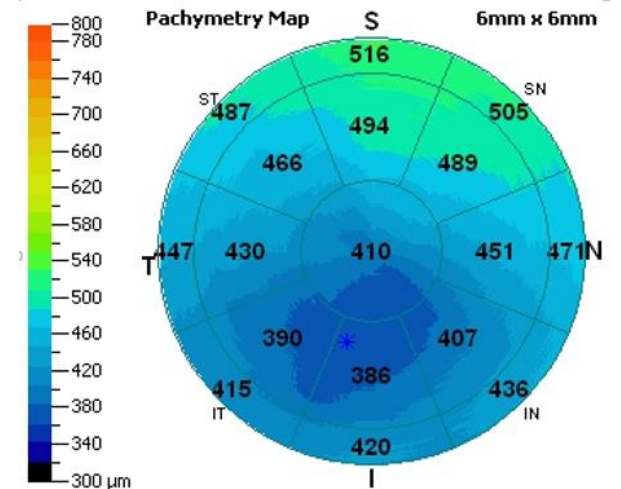
Std Dev: Min-Max:

Min/Max thickness indicated as */+



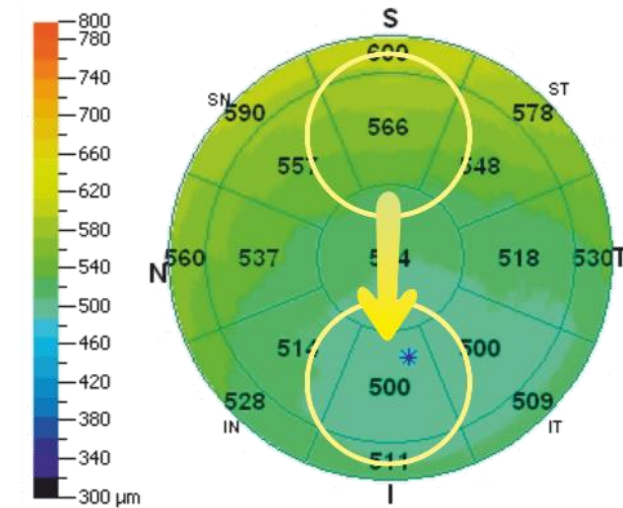
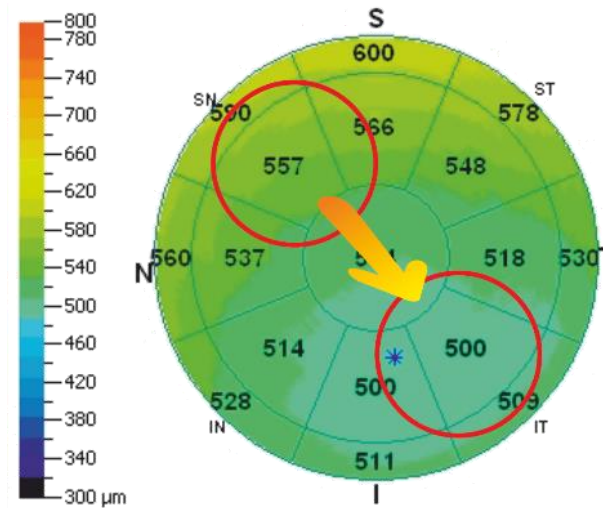
Κερατοειδής με κώνο

- Το συνολικό πάχος του επιθηλίου αυξήθηκε,
- πιθανώς ως αντίδραση στη λέπτυνση του συνολικού κερατοειδή

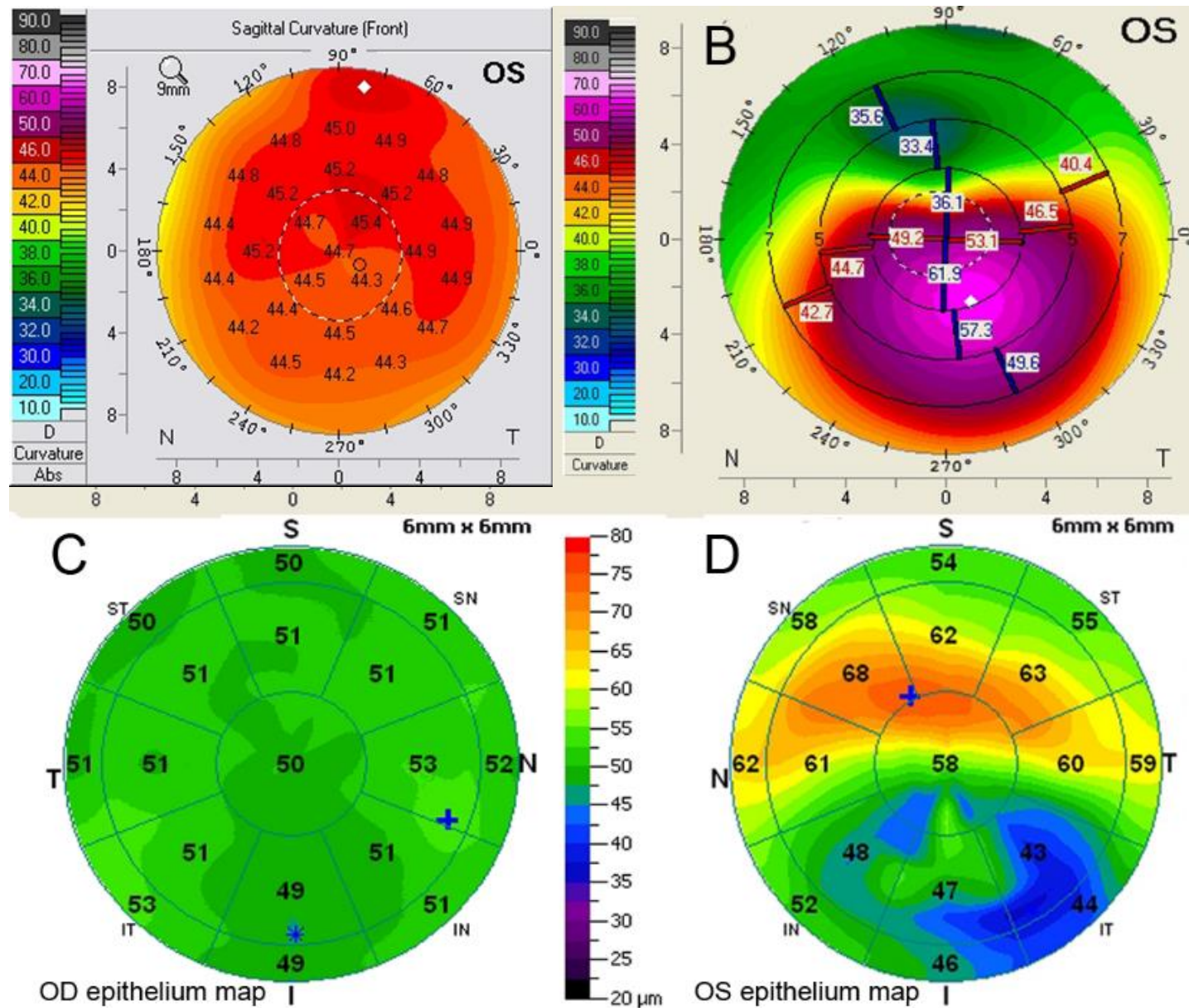


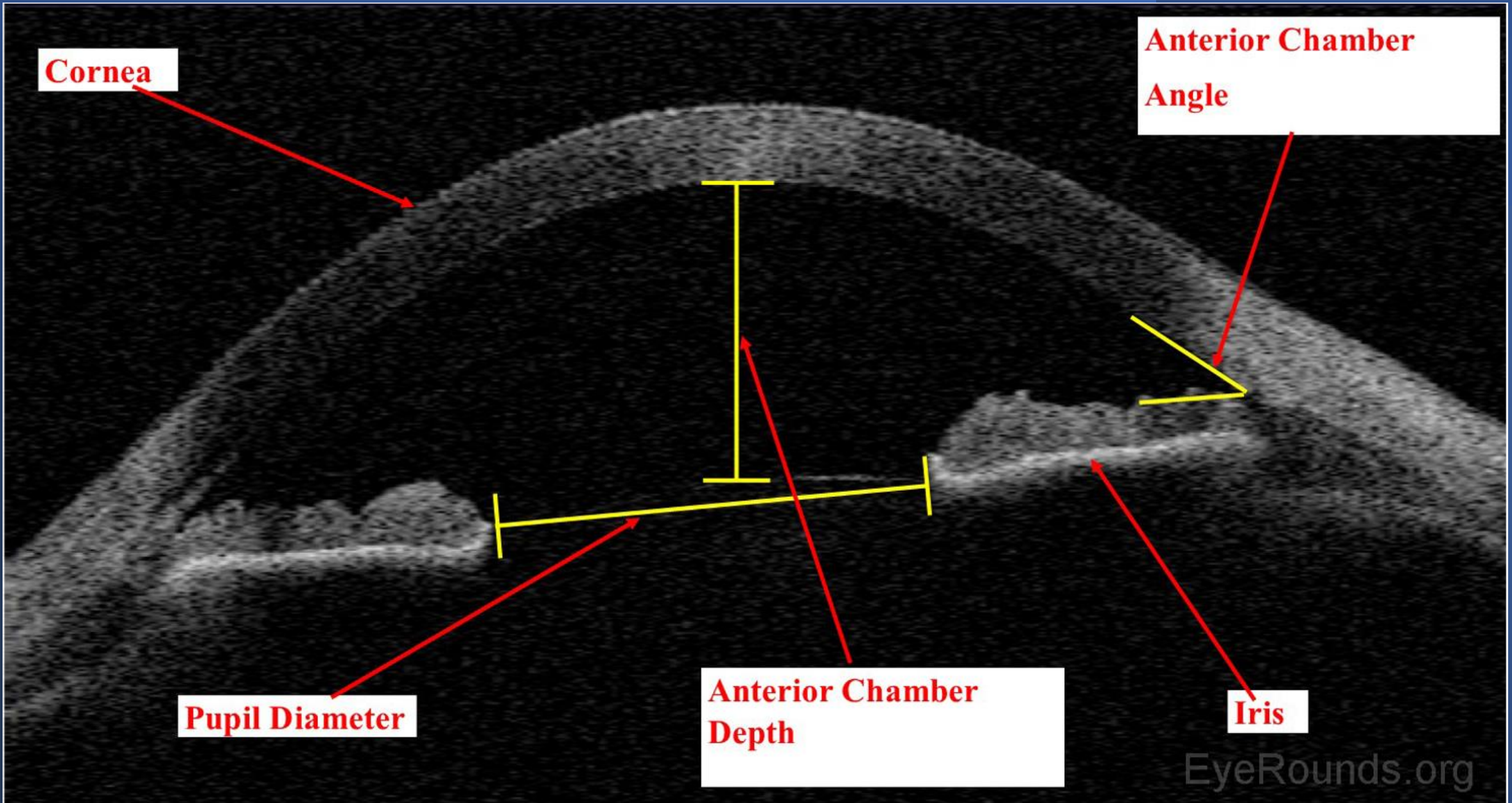
Corneal thickness irregularity

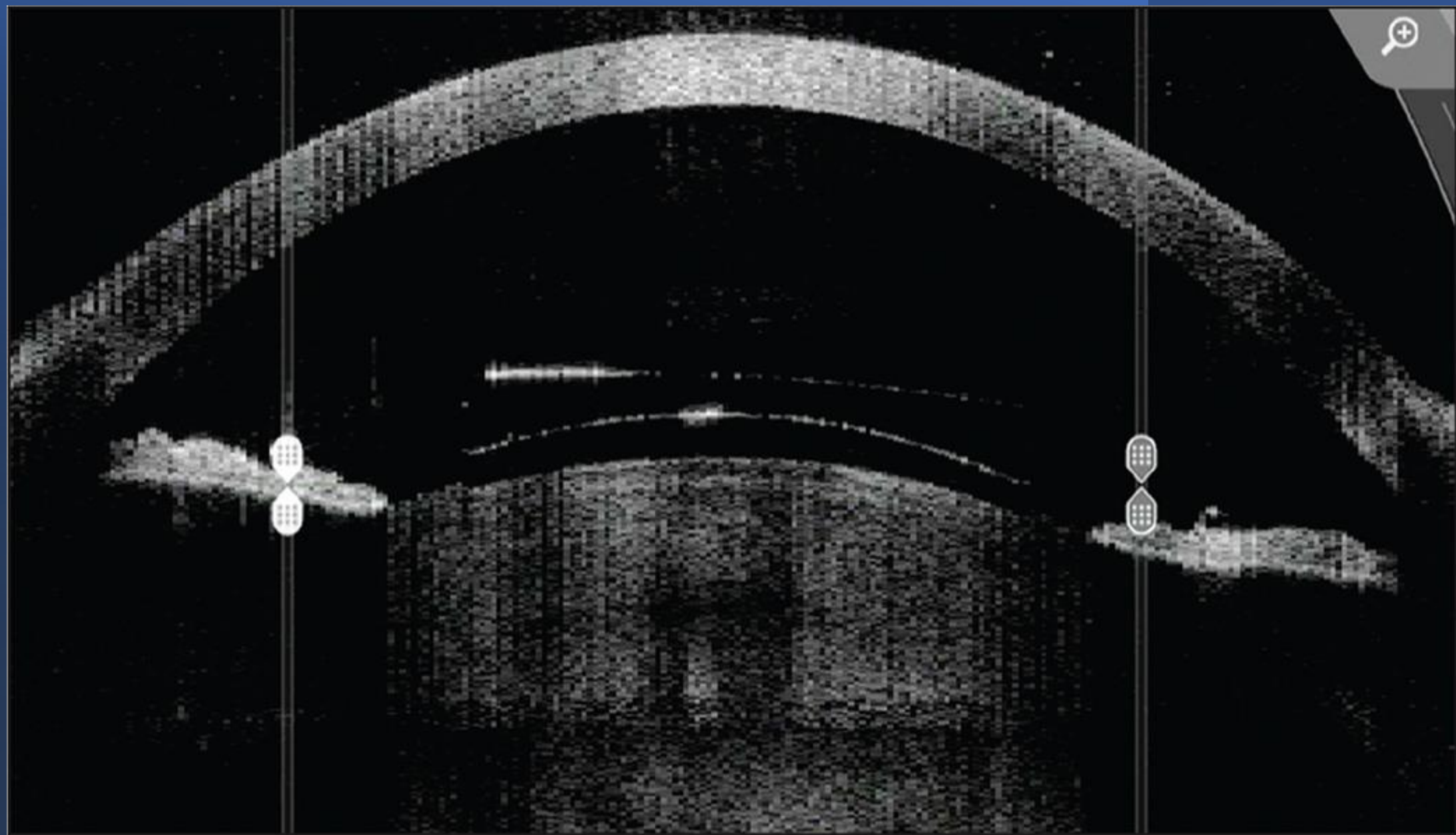
- Corneal thickness asymmetry indices
 - SN-IT, average superior-nasal octant thickness minus inferior-temporal;
 - S-I, superior minus inferior thickness
- Focal thinning indices
 - Min-Med focal thinning, minimum minus median thickness;
 - Min-Max thickness range, minimum minus maximum thickness.

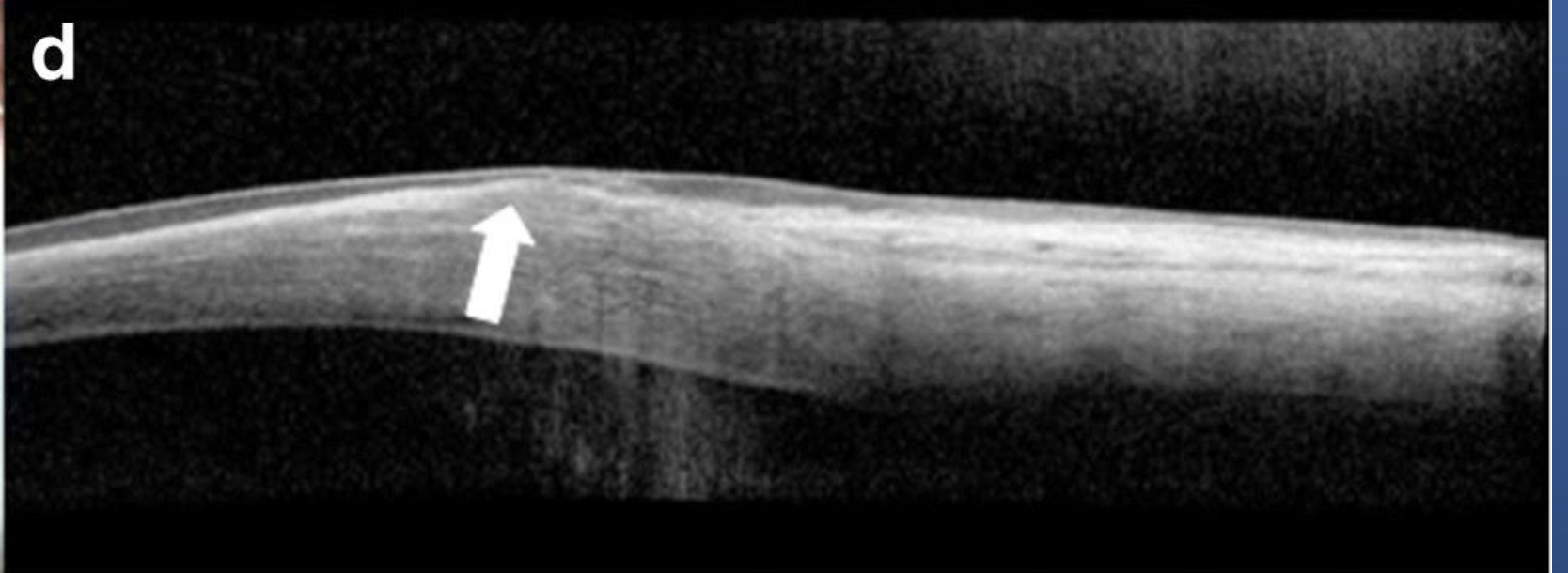
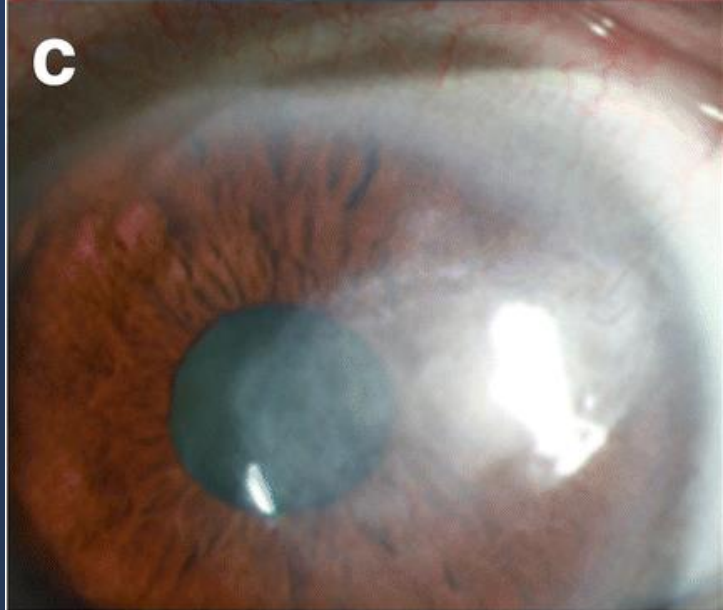
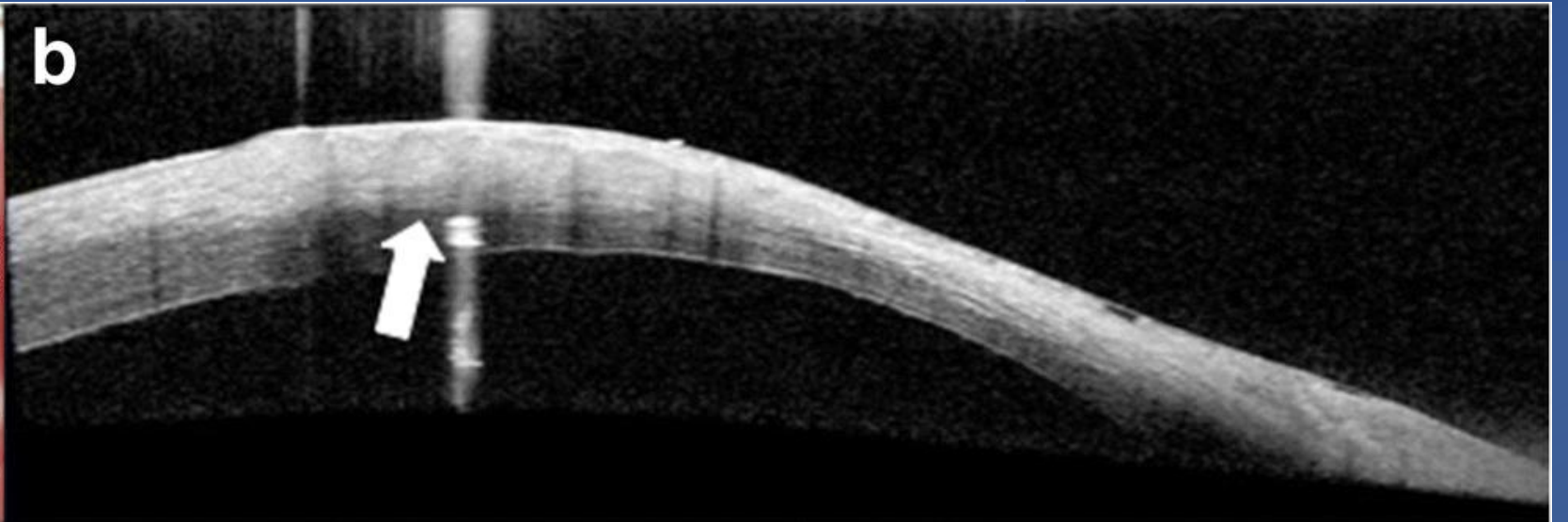
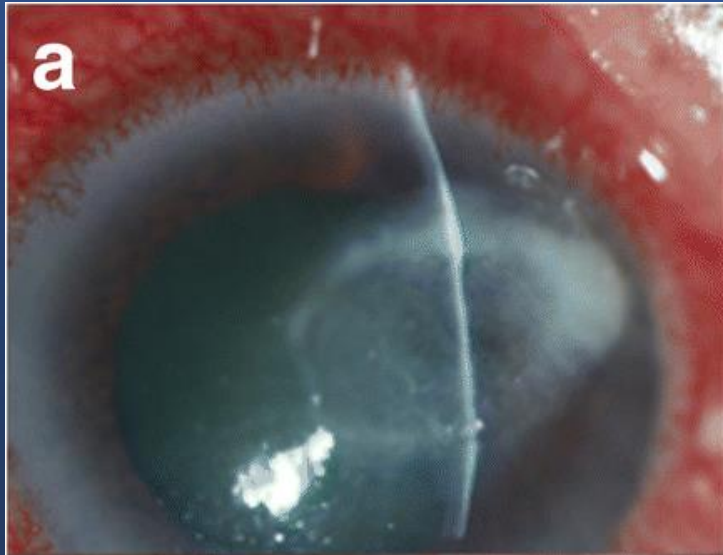


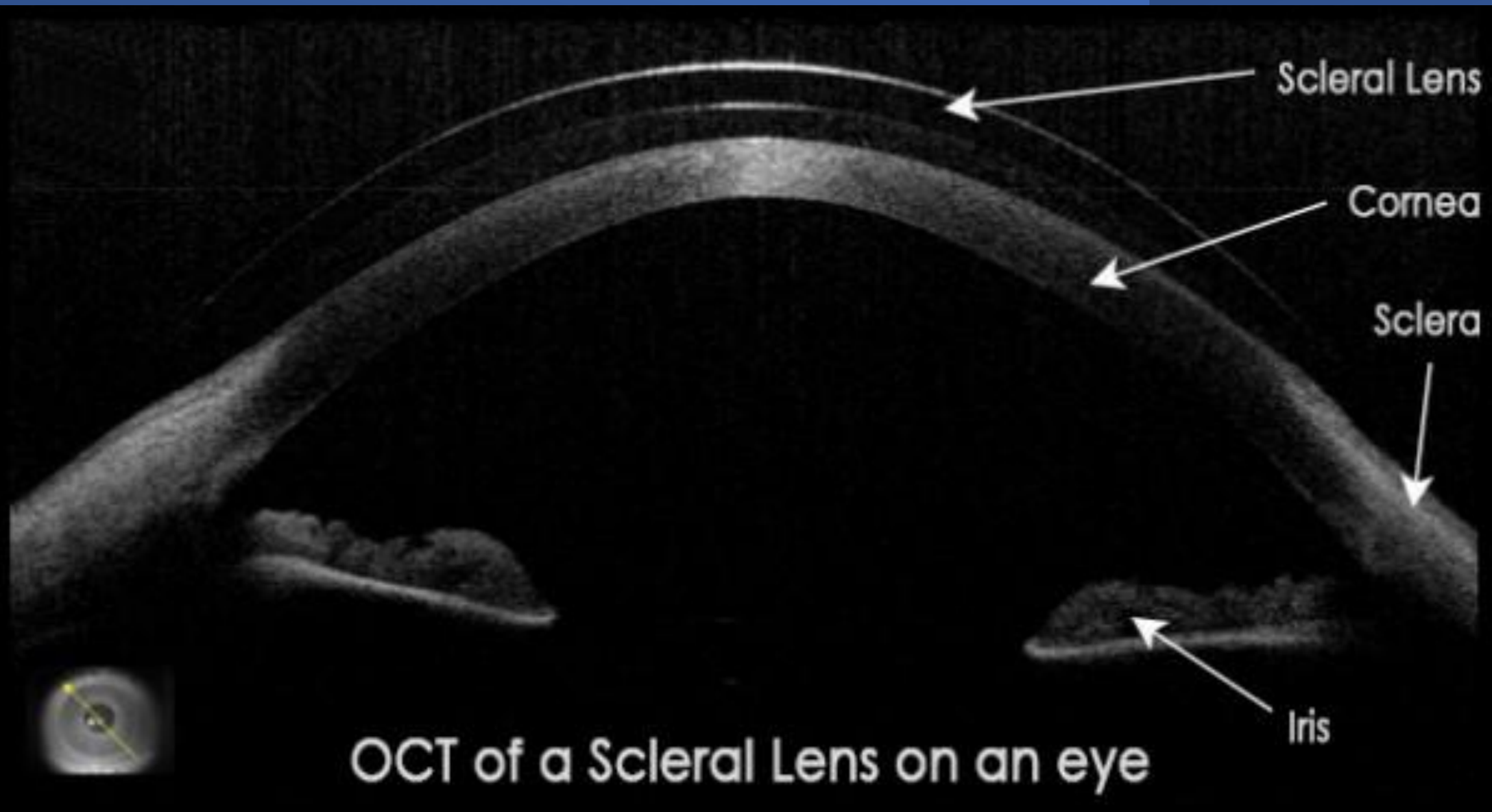
Τοπογραφία και ΟΣΤ κερατοειδούς







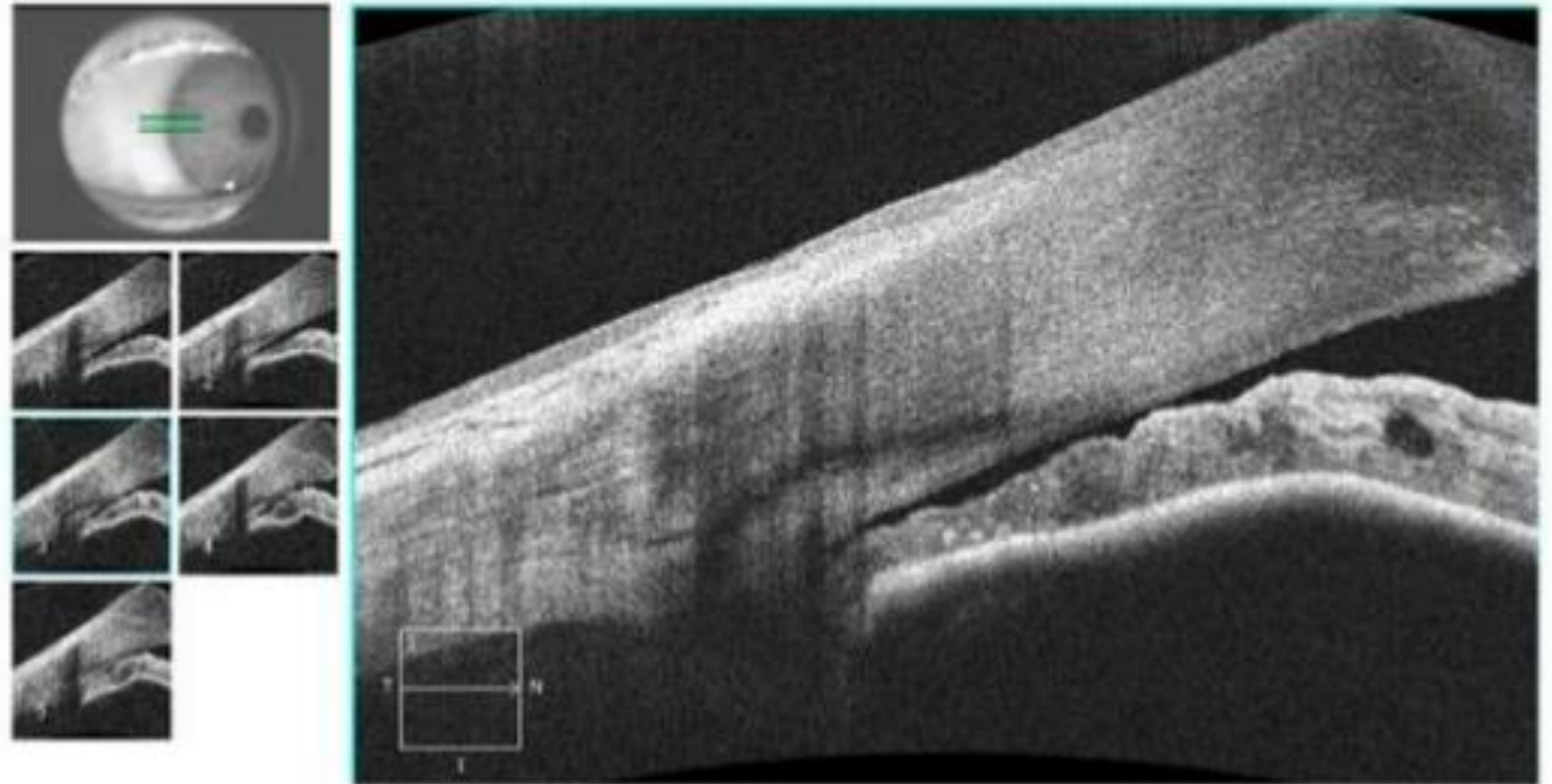




OCT of a Scleral Lens on an eye

Cirrus HD-OCT Anterior Segment Imaging

Γωνία
προσθίου
θαλάμου

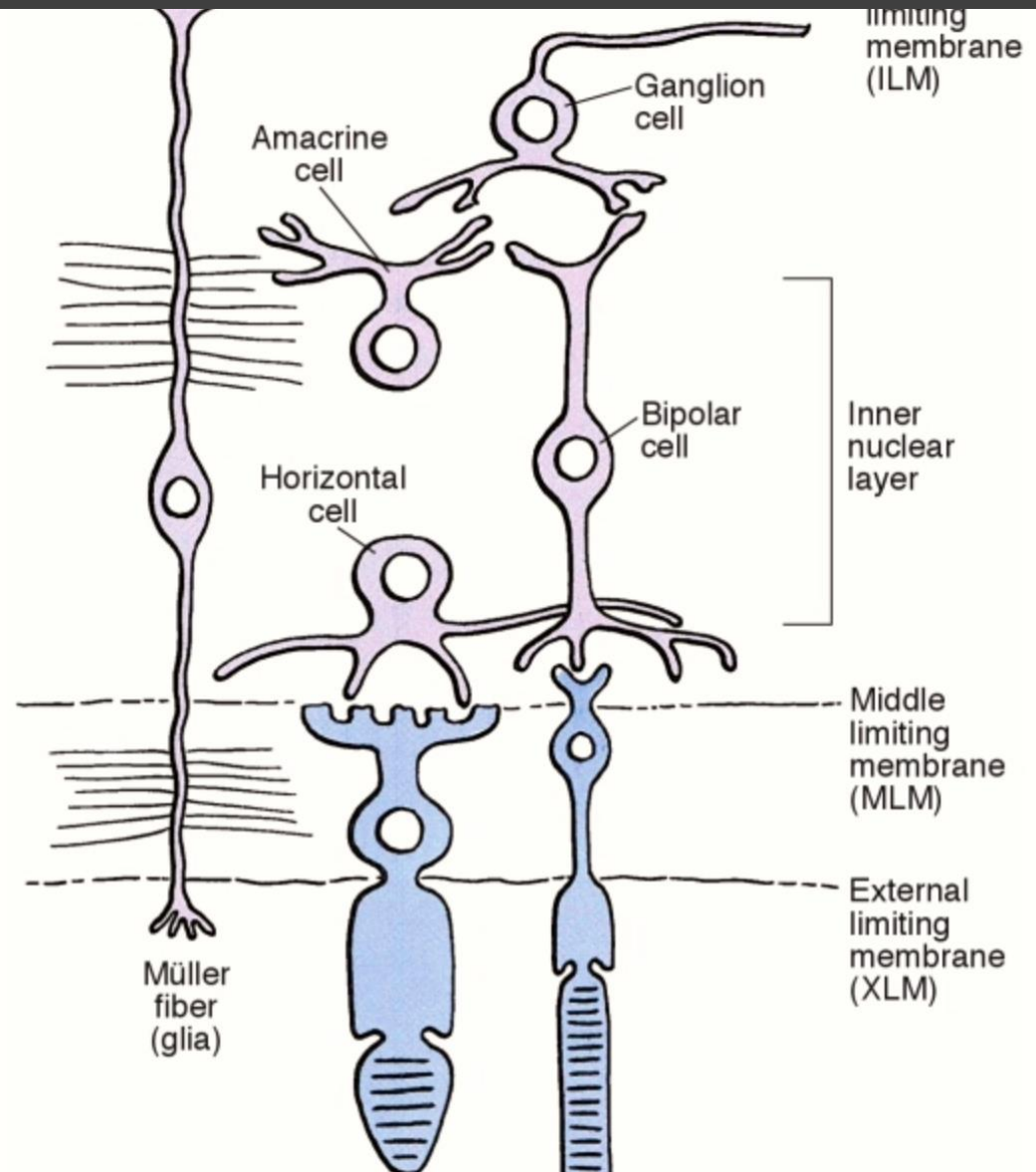

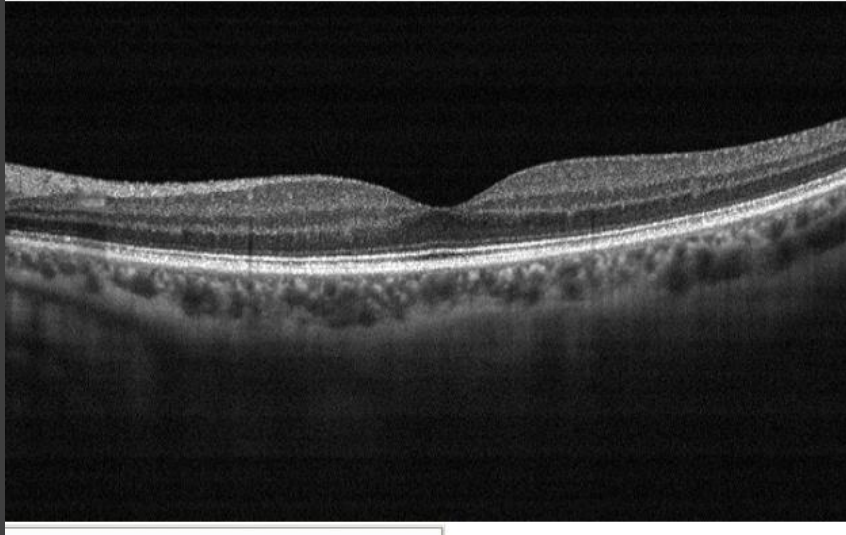


Images courtesy of Martha Leen, M.D. & Paul Kremer M.D. Achieve Eye and Laser Specialists, Silverdale, WA

Narrowing of angle of anterior chamber

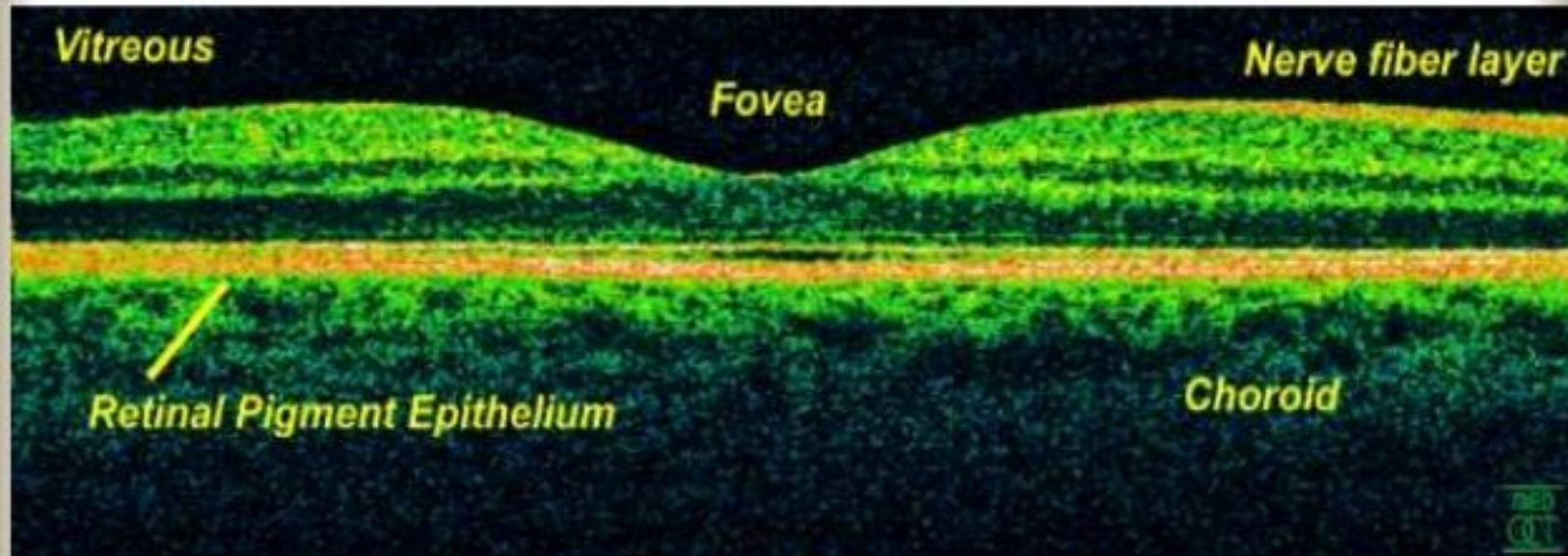
OCT Ωχράς Κηλίδος

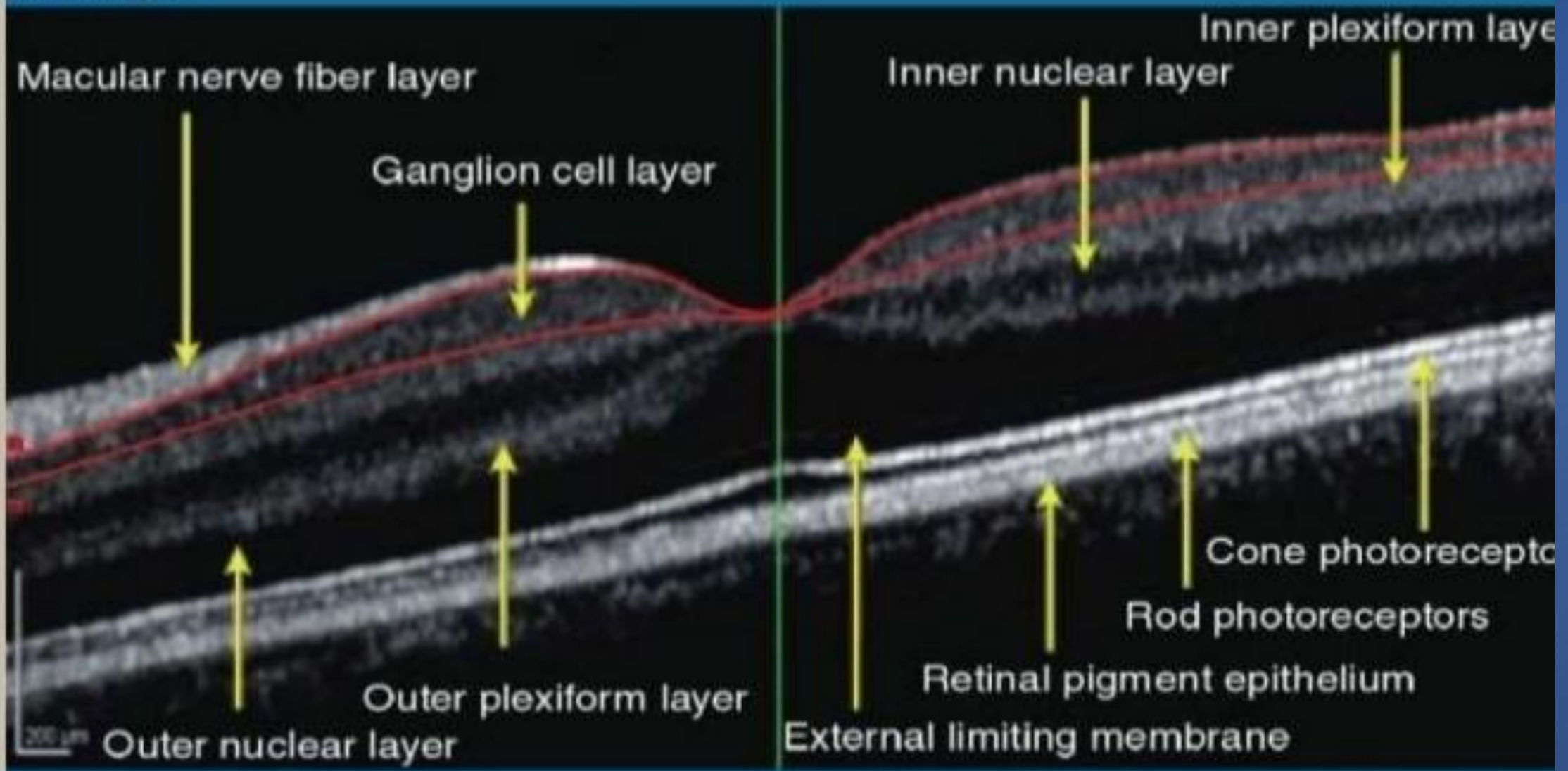
Line SSI= 53.7



COLOR CODING IN OCT

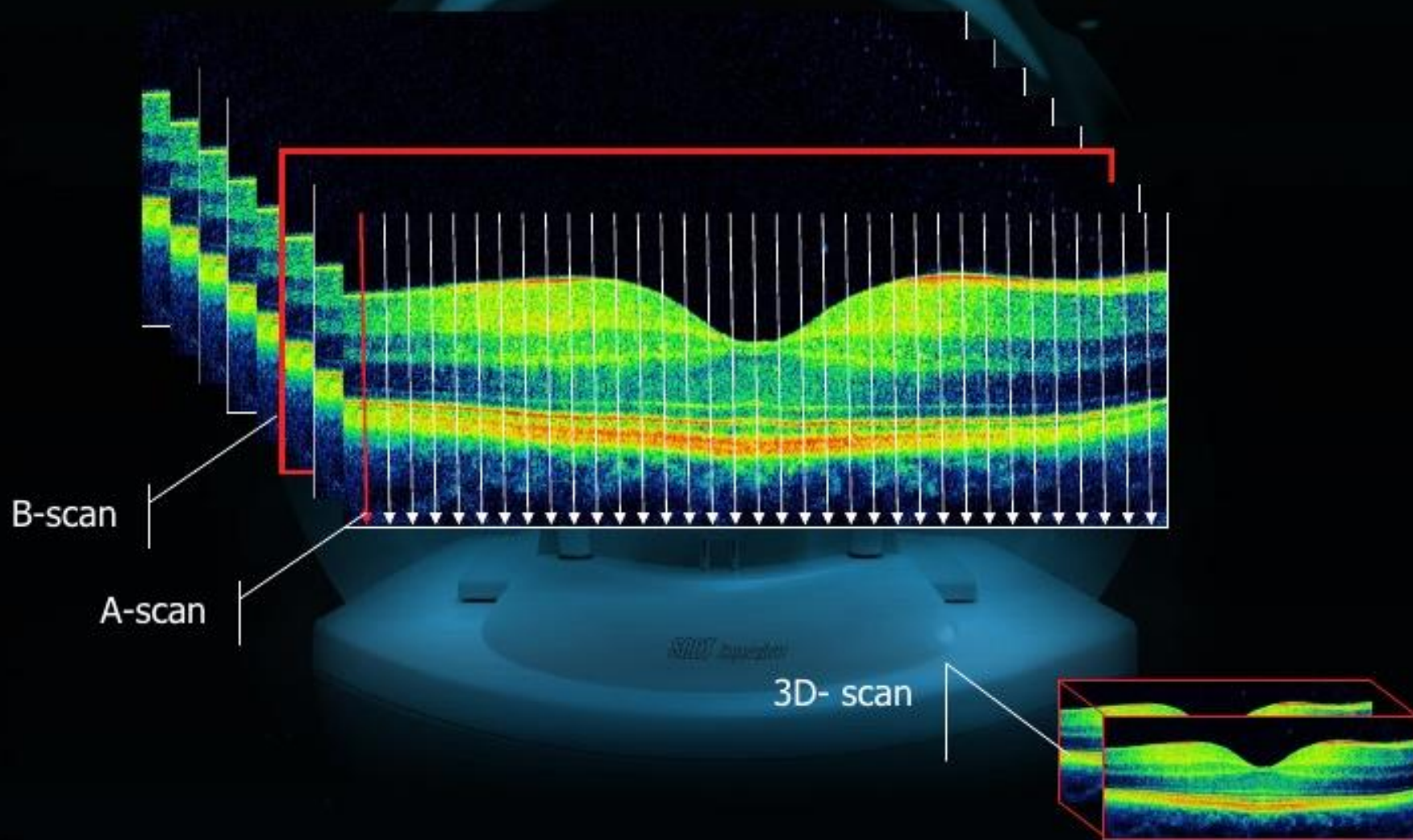
- Highly reflective structures are shown in bright colours (white and red) .
- Those with low reflectivity are represented by dark colours (black and blue).
- Intermediate reflectivity is shown **Green.**







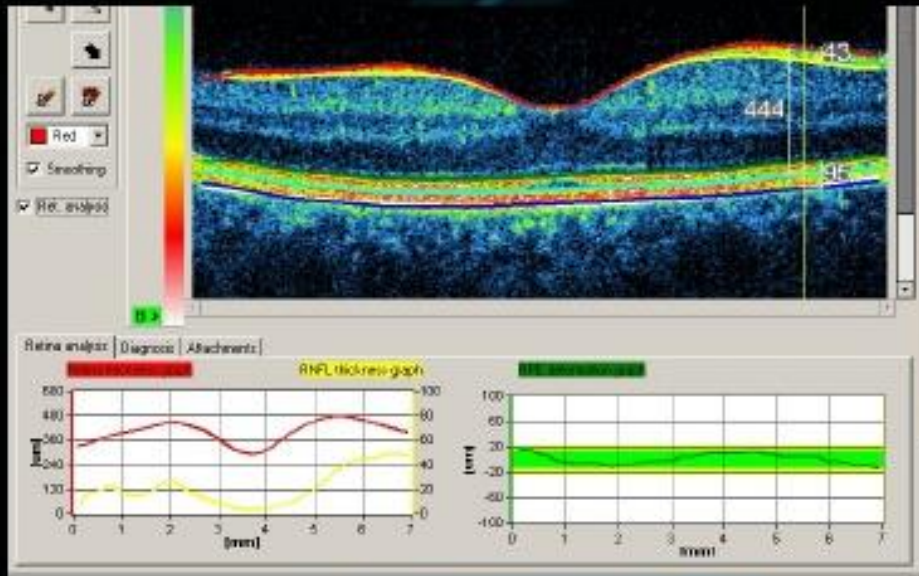
Terminology: A-scan, B-scan, 3D-scan





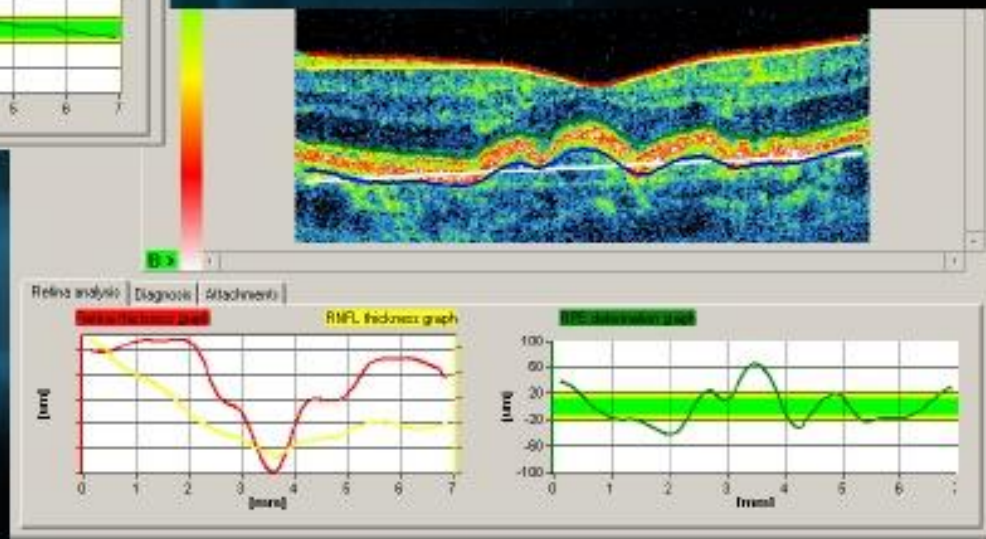
Results review

Automated Image analysis

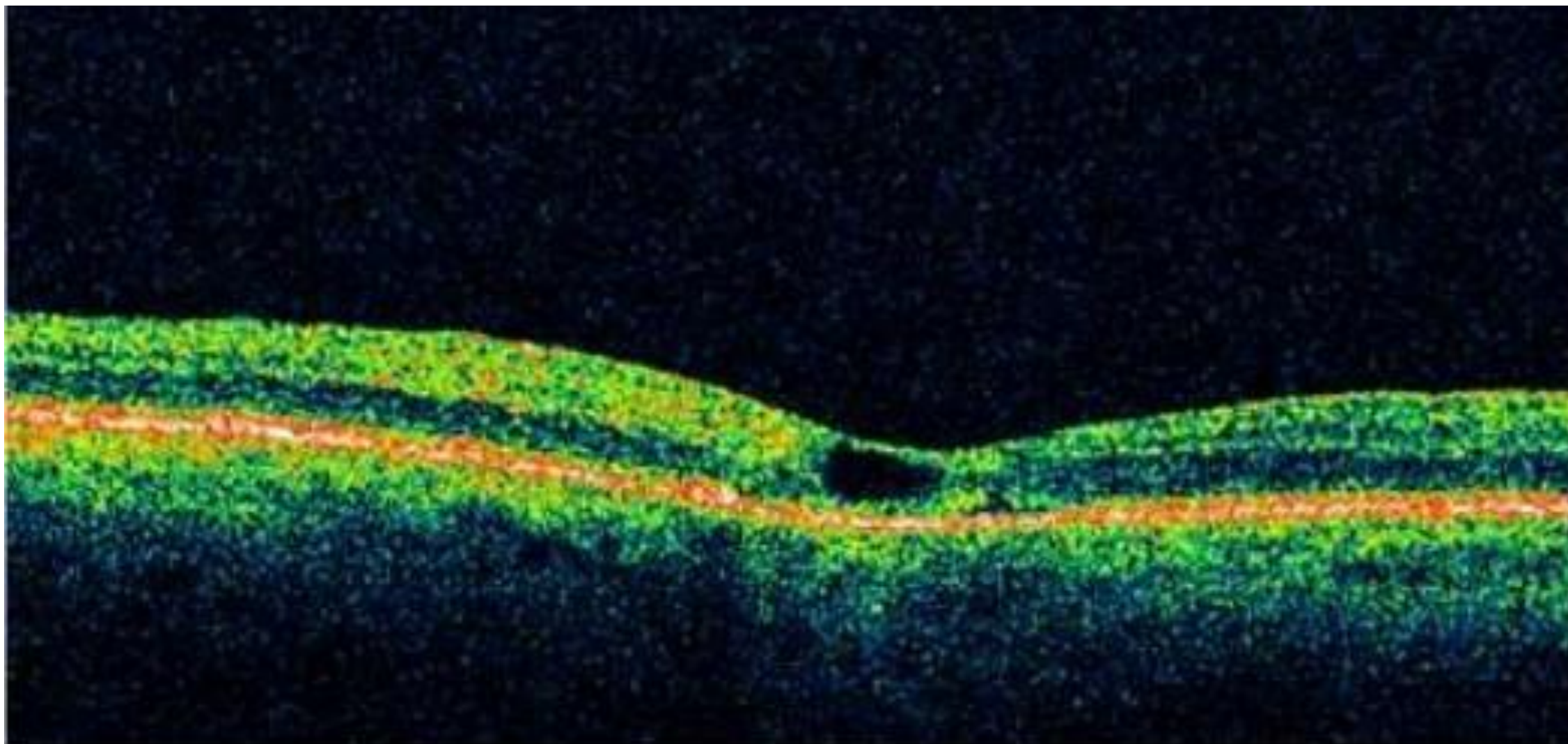


Normal retina

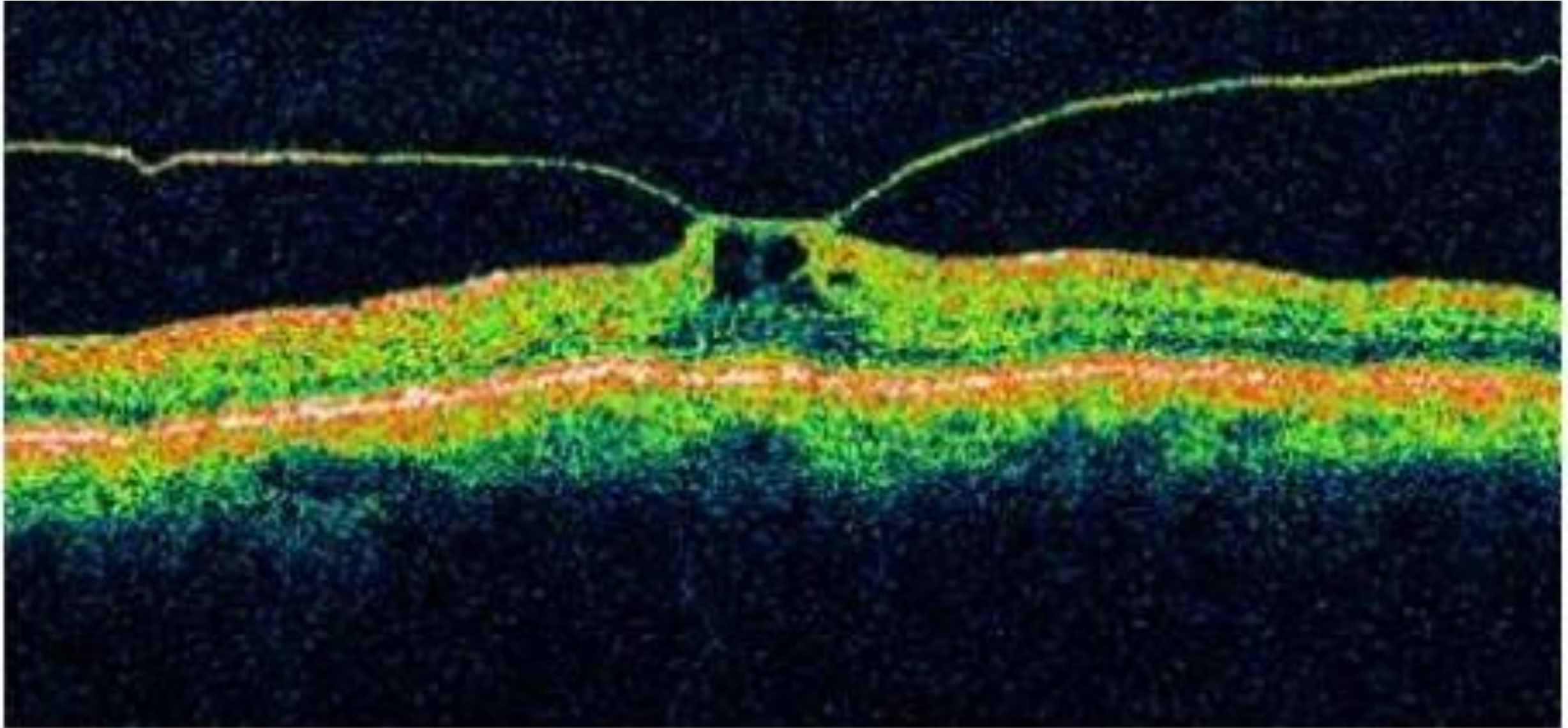
Pathology (Drusen) →



Κύστη Ωχράς




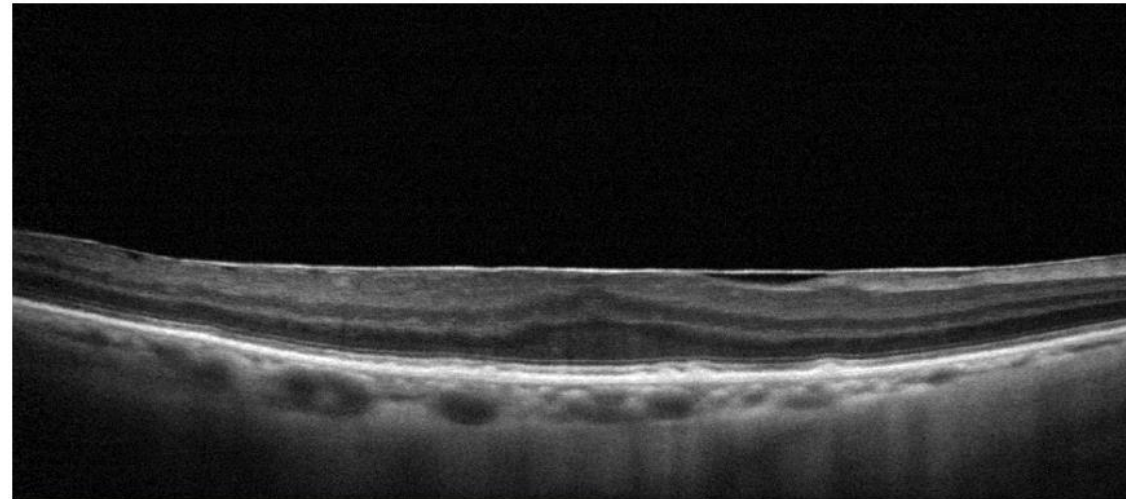
Επιαμφιβληστροειδική μεμβράνη



Επιαμφιβληστροειδική μεμβράνη

DOB (age): 02/27/1937 (77) Disease: Operator:
ID: Algorithm Version: A6, 9, 0, 27 Exam Date: 06/04/2014
Gender: M Physician:

OD Line SSI= 51.9 6.00mm Scan Length



of Averages:30

Average

No Average

Diagnosis:

Diabetic Maculopathy

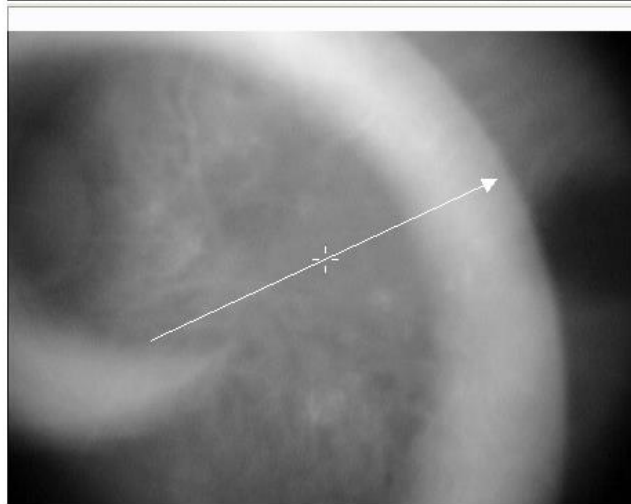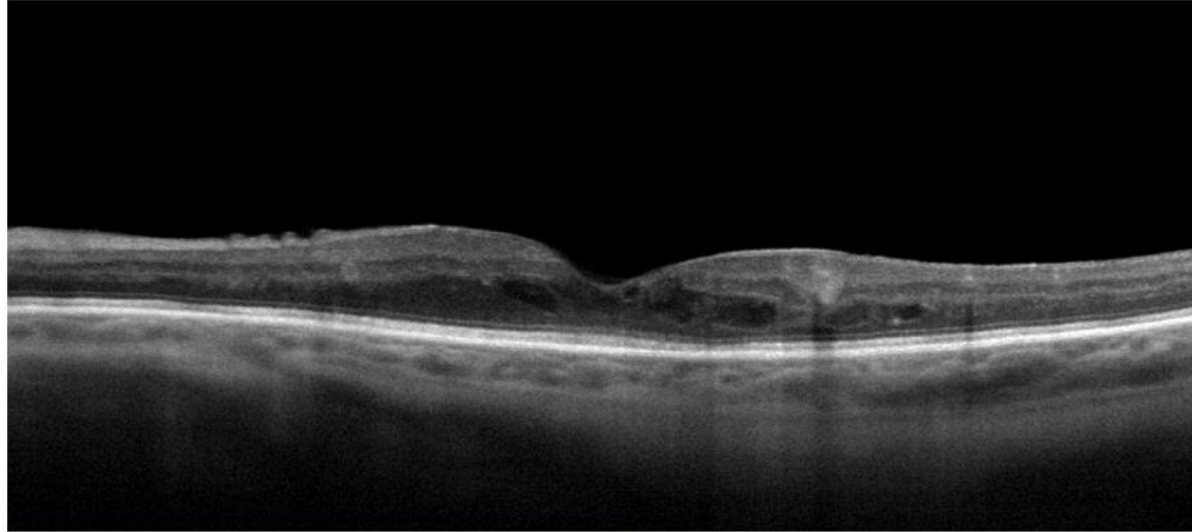
Patient: [REDACTED] Disease: DIABETIC M. MALE Operator: [REDACTED]
DOB (age): 07/07/1946 (68) Algorithm Version: A6, 9, 0, 27 Exam Date: 11/21/2014
ID: [REDACTED] Gender: M Physician: [REDACTED]

05

Line

SSI= 61.0

6.00mm Scan Length



of Averages:32

Average

No Average

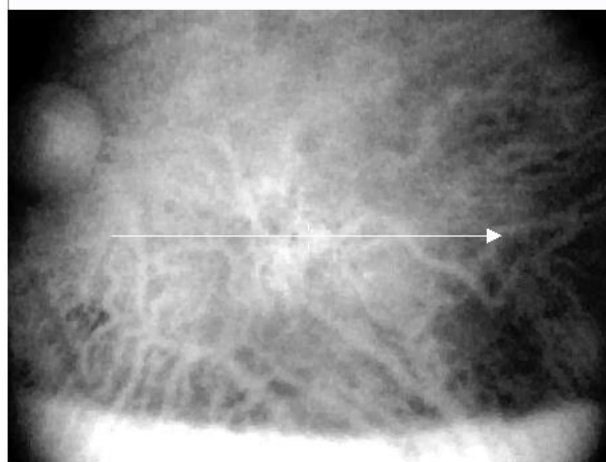
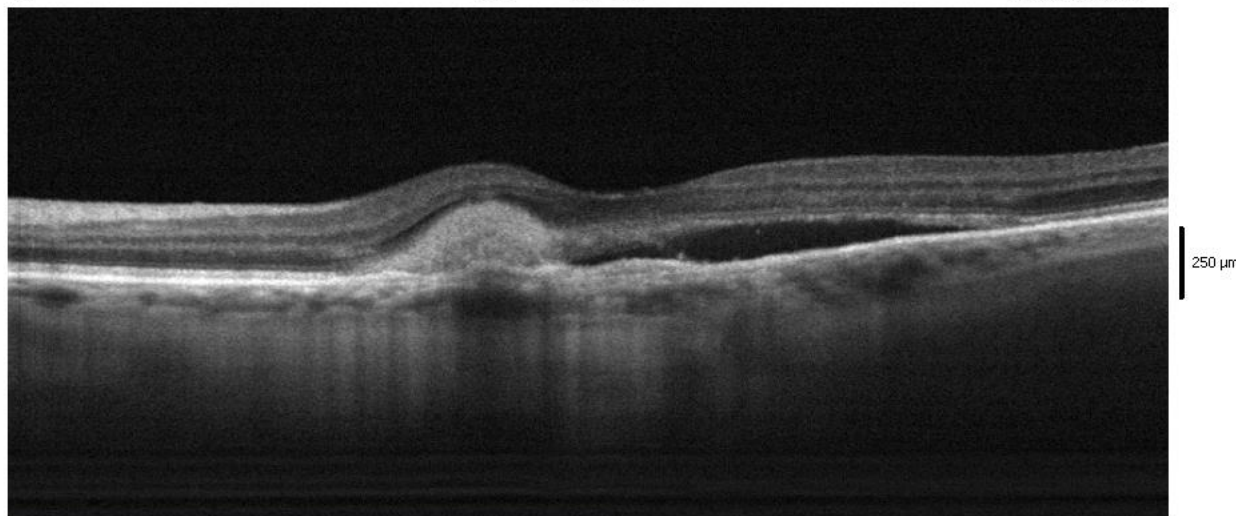
Diagnosis:

[Empty text box for diagnosis]

WET AMD – Εκφύλιση ωχράς κηλίδος υγρής μορφής

Patient: [REDACTED] Disease: cataract clear cut Operator:
DOB (age): 06/28/1933 (81) Algorithm Version: A6, 9, 0, 27 Exam Date: 04/22/2013
ID: Gender: M Physician:

05 Line SSI= 46.6 6.00mm Scan Length



of Averages:31

Average

No Average

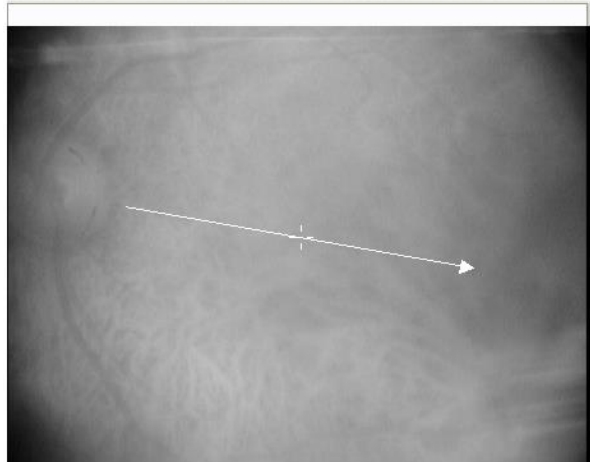
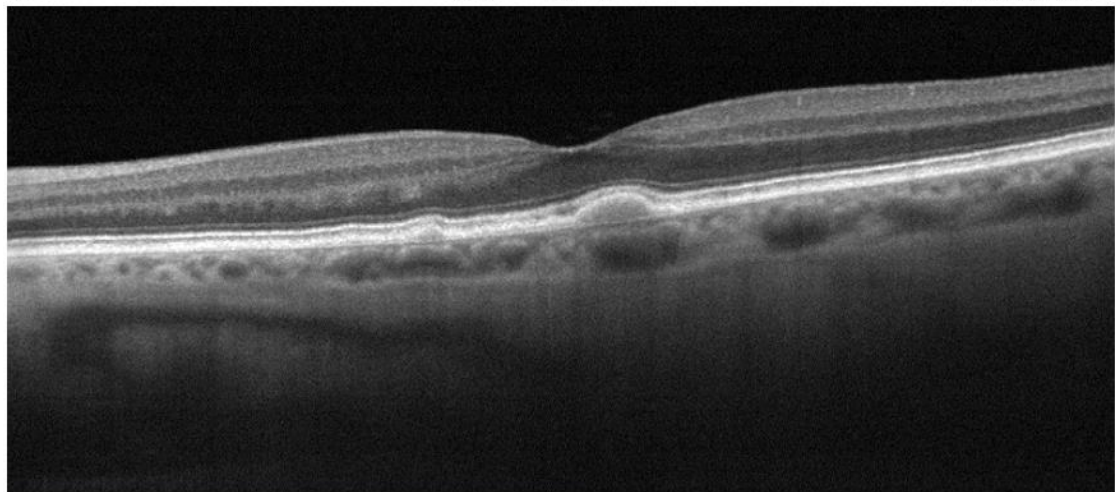
Diagnosis:

[Empty text box for diagnosis]

DRY AMD- Εκφύλιση ωχράς κηλίδος ξηρής μορφής

Patient: [REDACTED] Disease: Algorithm Ver: A6, 11, 0, 12 Operator: Exam Date: 09/24/2014
DOB(age): 04/12/1937 (77) Gender: F Physician:

OS Line SSI= 72.6 6.00mm Scan Length



of Averages:32

Average

No Average

Auto Zoom

Diagnosis:

[Empty text box for diagnosis]

Αιμορραγία αμφιβληστροειδούς

DOB(age): 01/01/1936 (79)
ID:

Algorithm Ver: A6, 11, 0, 12
Gender: F

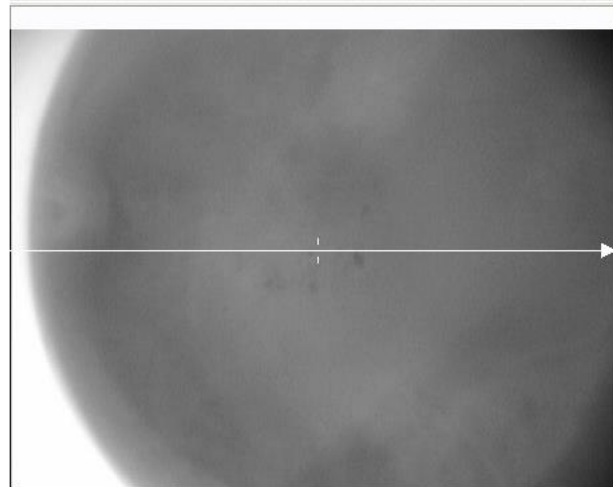
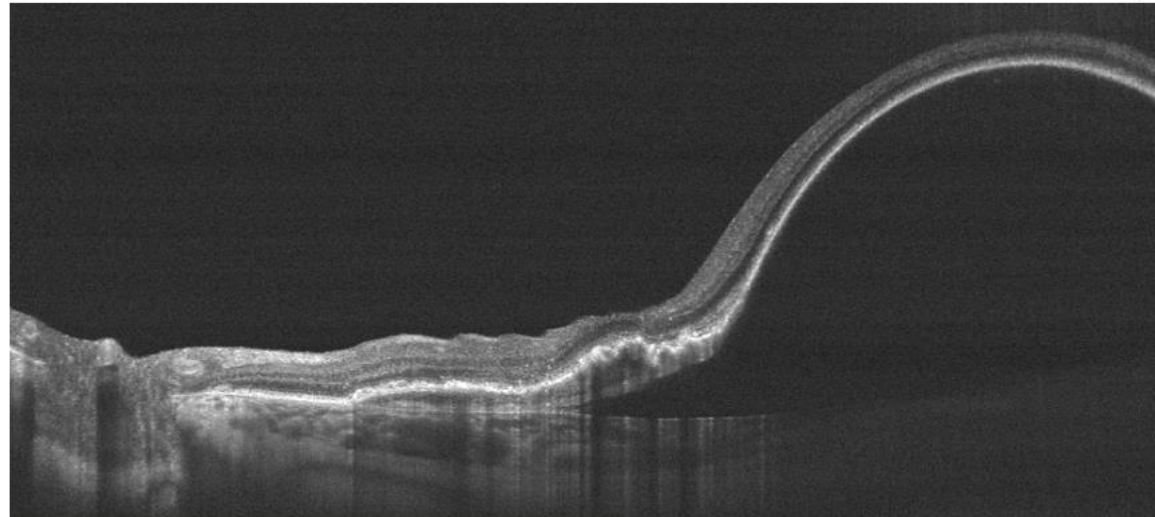
Exam Date: 01/12/2015
Physician:

05

Line

SSI= 51.5

10.00mm Scan Length



of Averages:23

Average

No Average

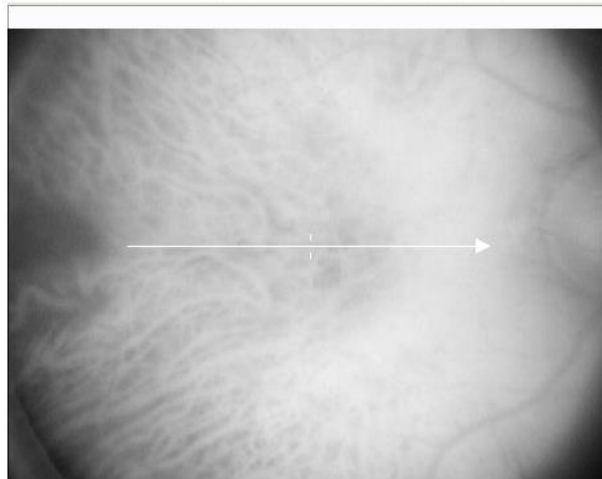
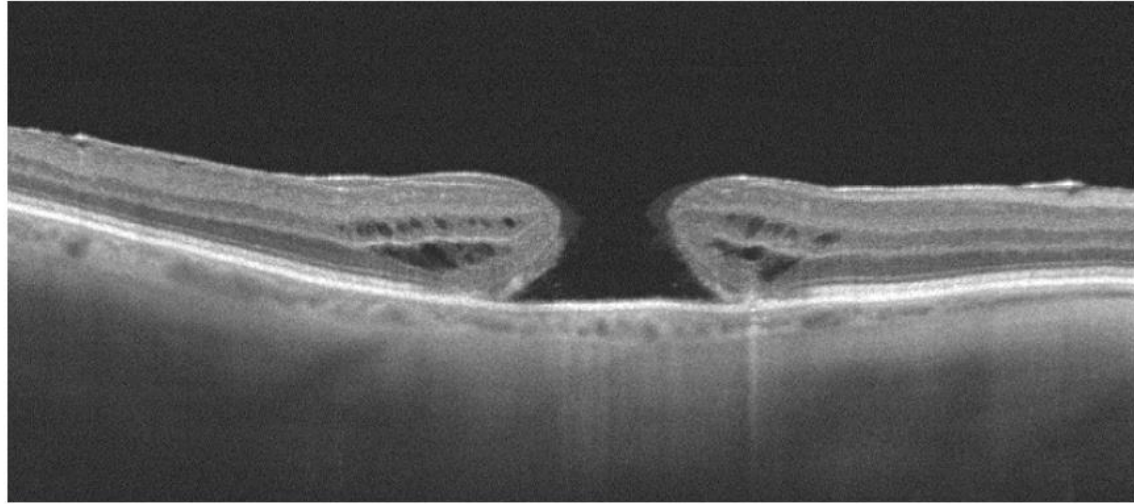
Auto Zoom

Diagnosis:

Οπή Ωχράς

Patient: [REDACTED] Disease: Operator:
DOB(age): 11/07/1938 (76) Algorithm Ver: A6, 11, 0, 12 Exam Date: 09/12/2014
ID: Gender: F Physician:

OD Line SSI= 73.4 6.00mm Scan Length



of Averages:27

Average

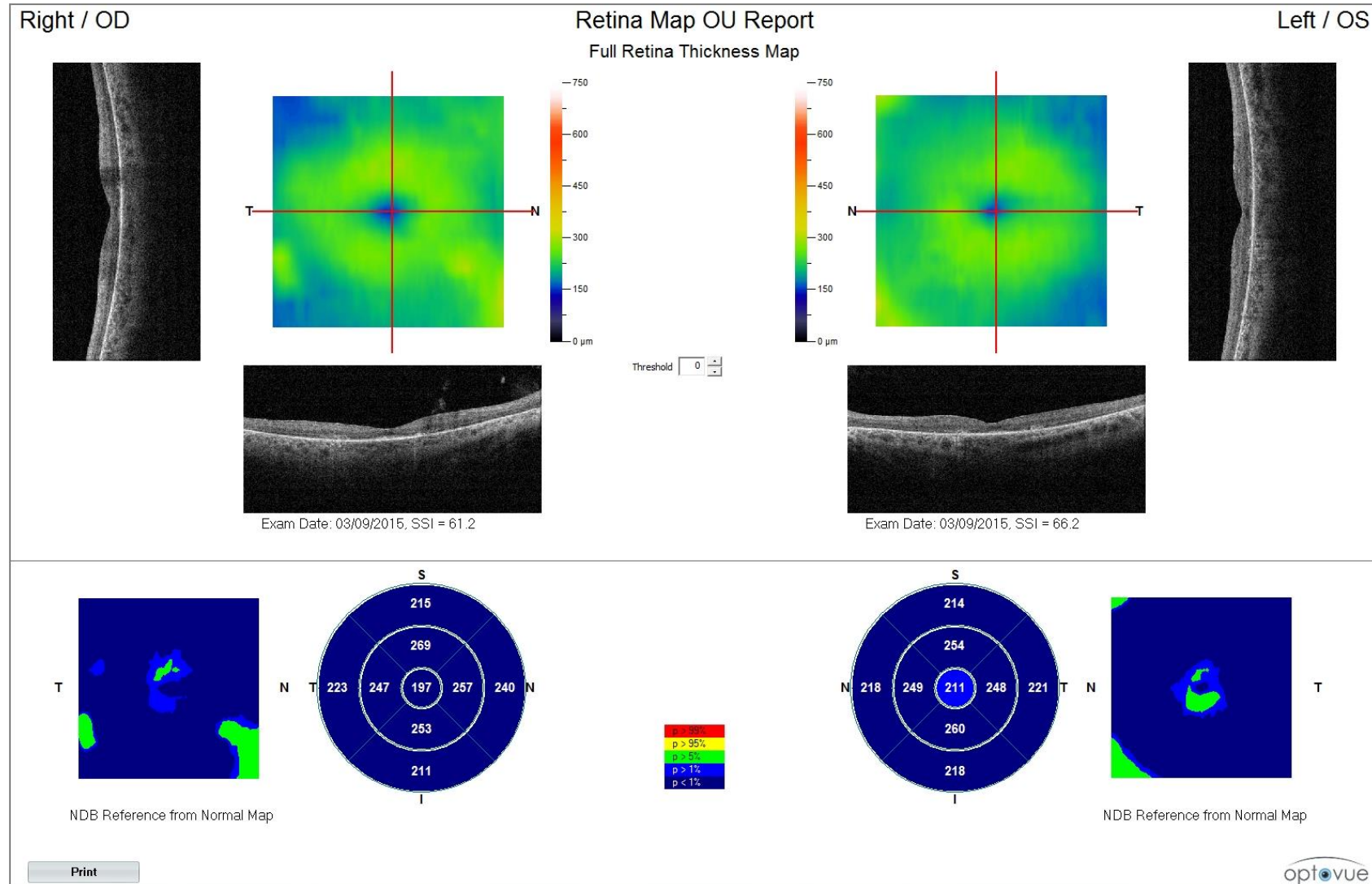
No Average

Auto Zoom

Diagnosis:

[Empty text box for diagnosis]

RP – Μελαγχρωστική αμφιβληστροειδοπάθεια



ANGIO OCT OU REPORT

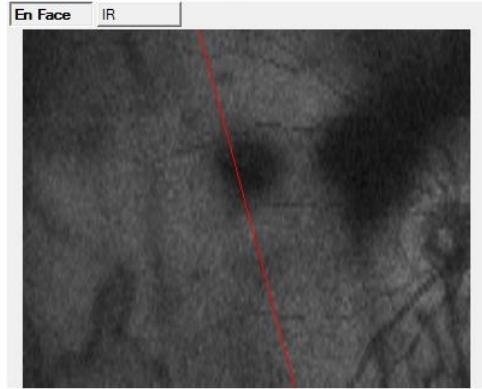Right / OD

Scan 03/04/2015 16:54:29

Enhanced HD Line OU Report

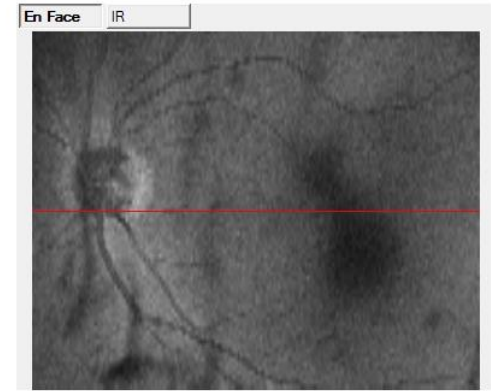
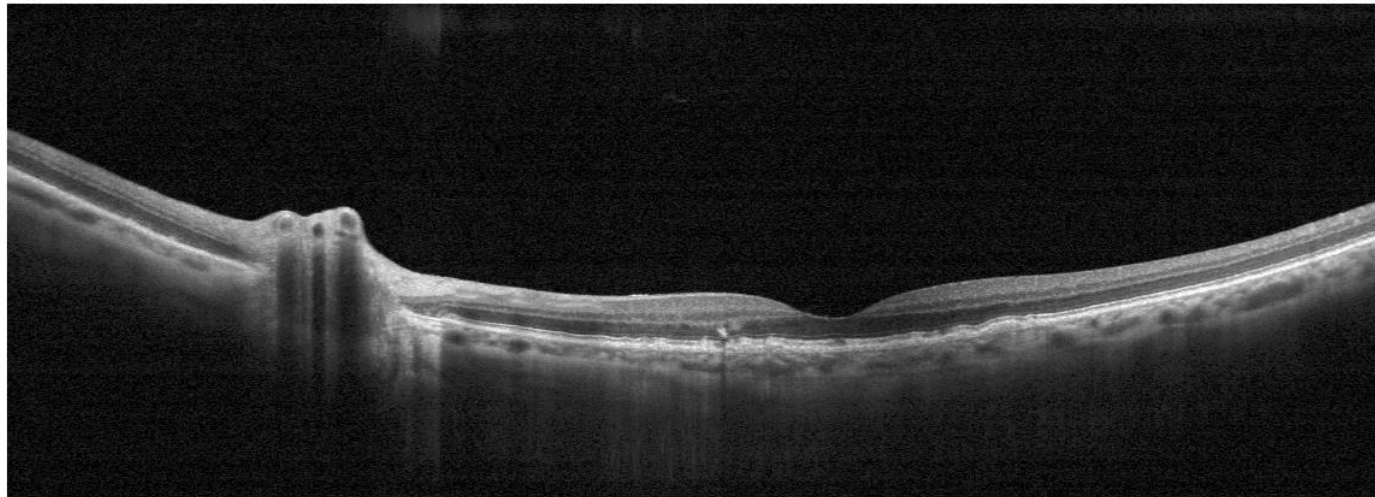
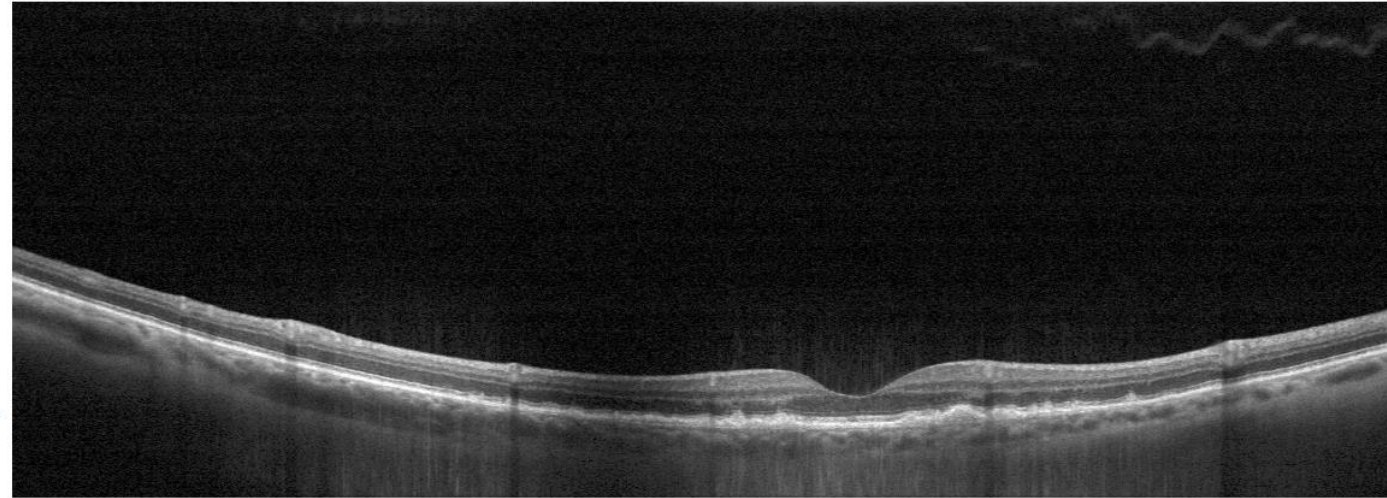
Signal Strength Index 46

12.00 Scan Size (mm)



1

250µm



250µm

1

Scan 03/04/2015 16:55:59

Left / OS

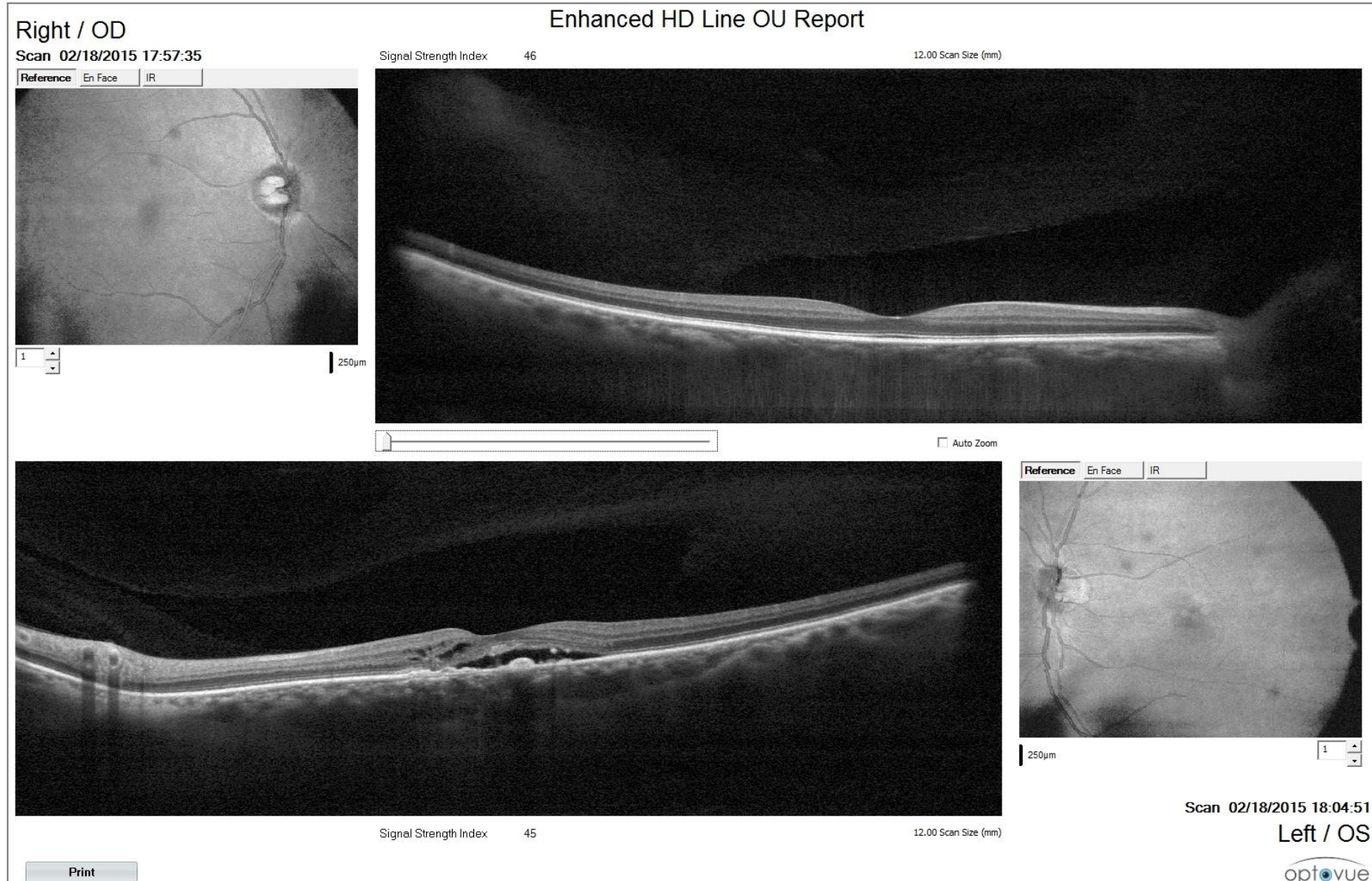
Signal Strength Index 55

12.00 Scan Size (mm)

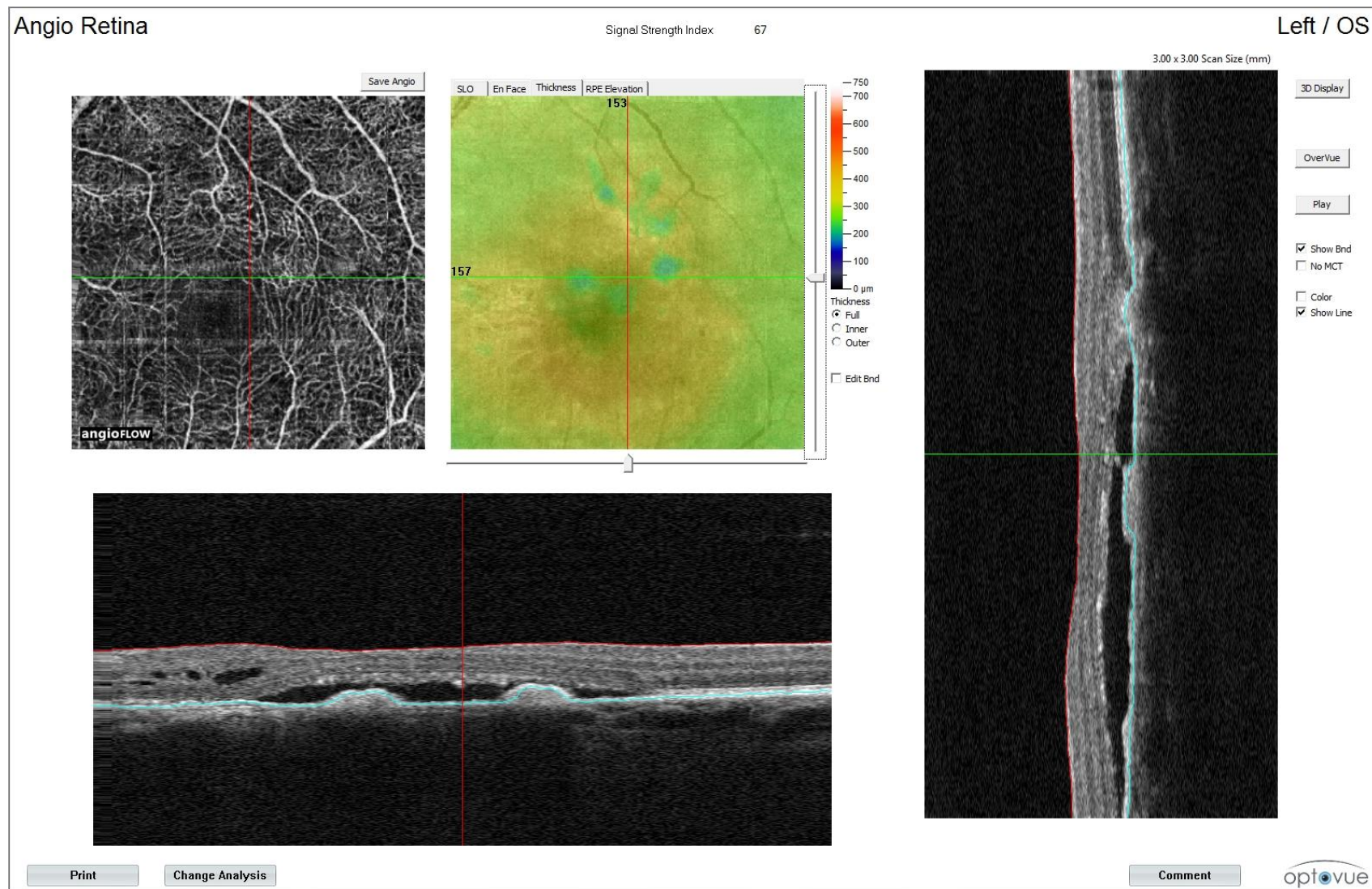
Print

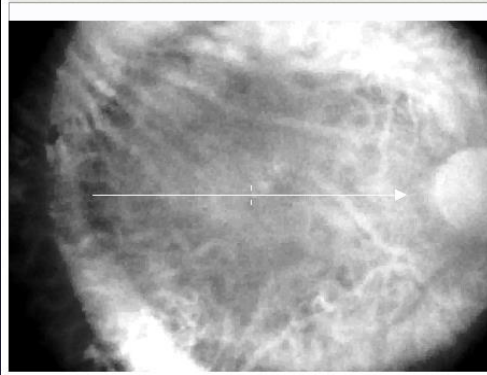
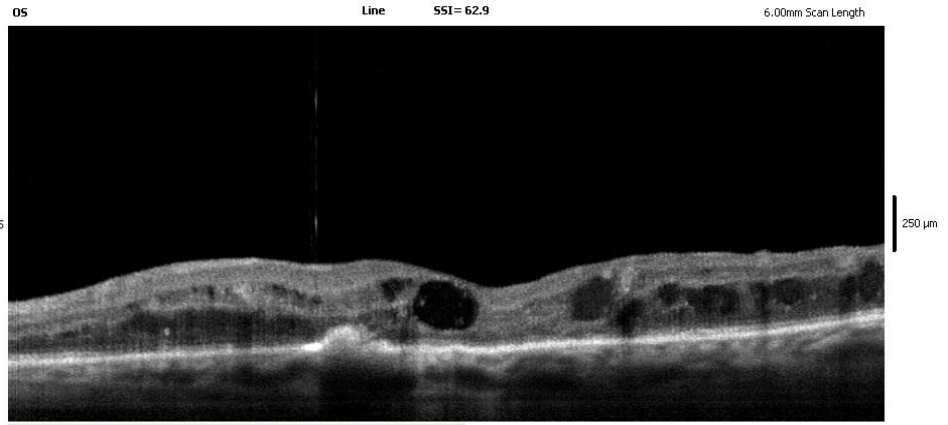
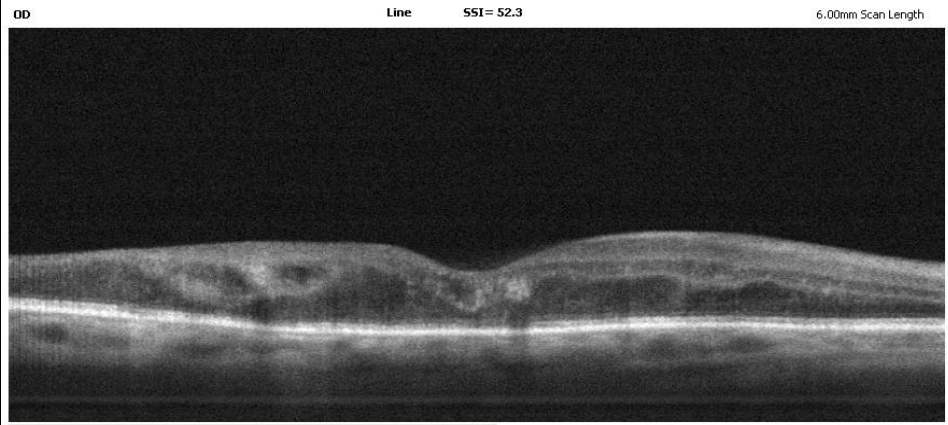
optovue

ANGIO OCT – ΟΙΔΗΜΑ Α.Ο.

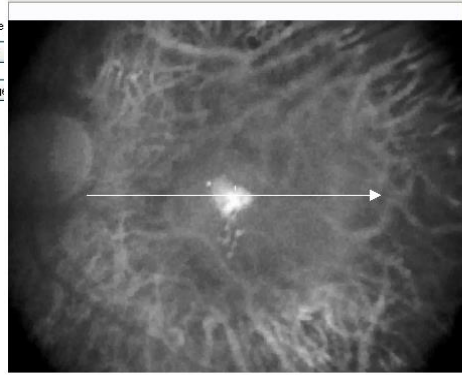


ANGIO OCT - ΟΙΔΗΜΑ ΩΧΡΑΣ





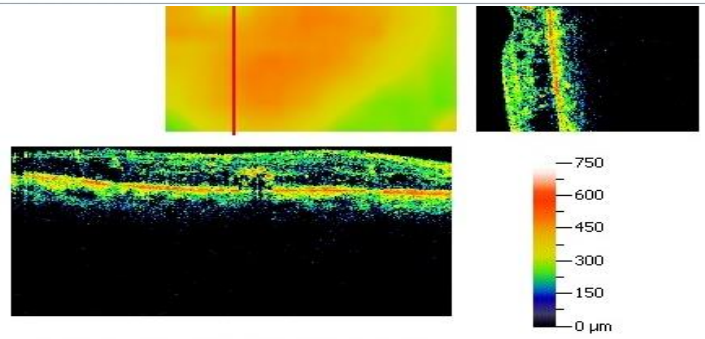
of Average
Average
No Average




of Averages: 15
Average
No Average

Diagnosis:

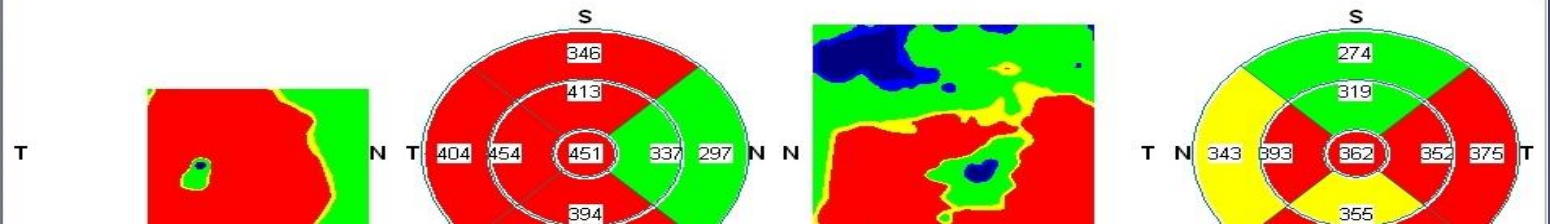
Diagnosis:



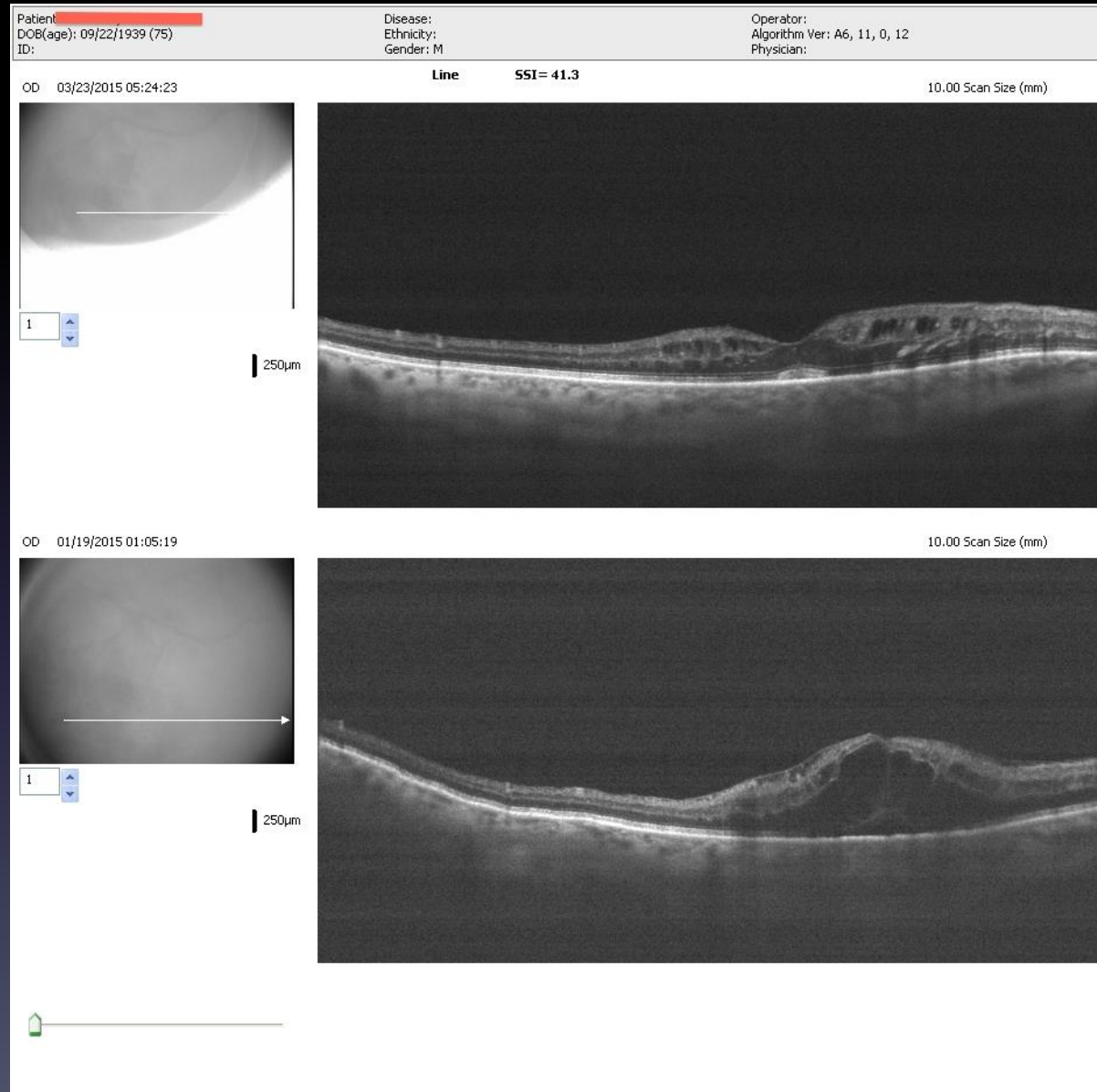
Exam Date: 04/21/2010, SSI= 50.2



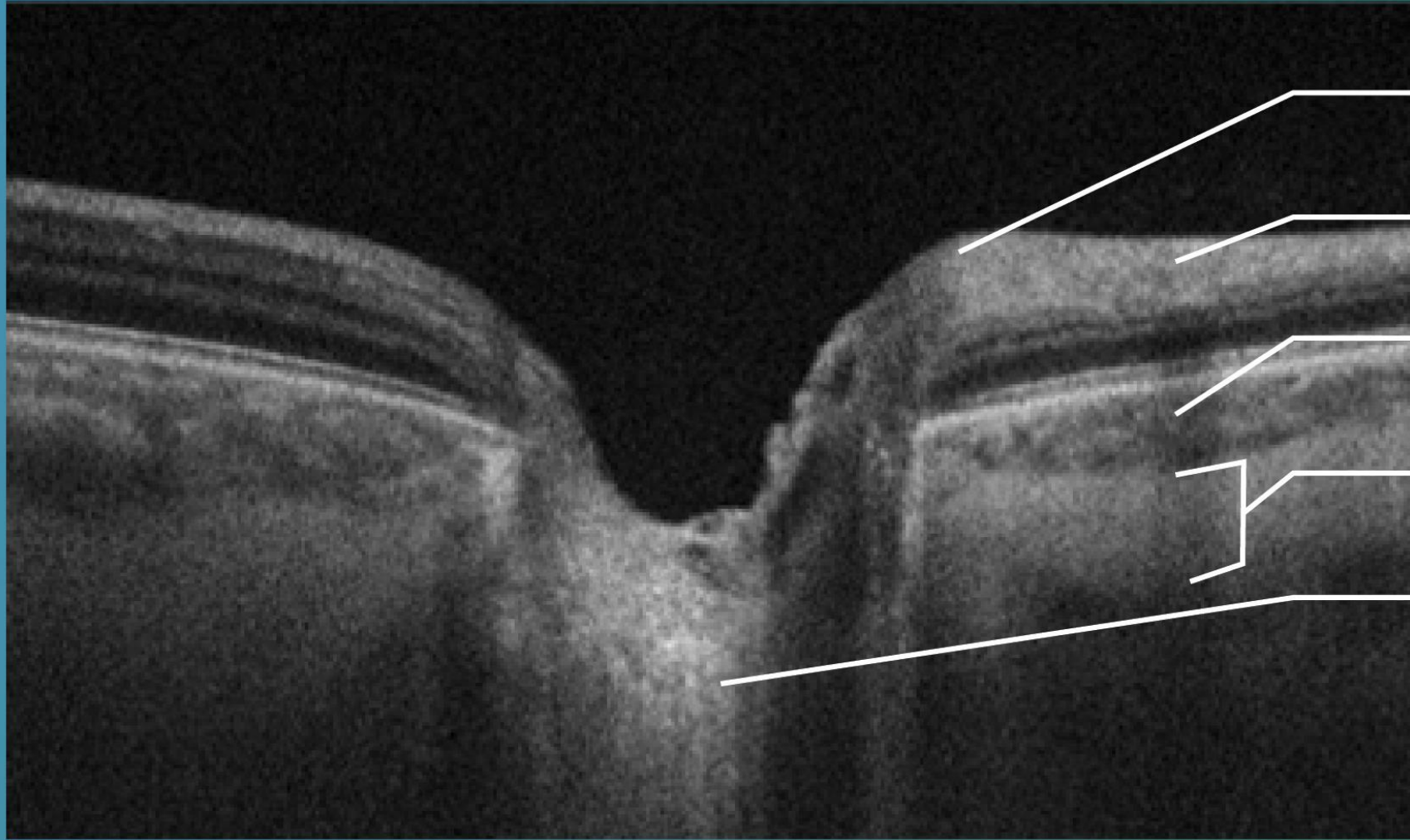
Exam Date: 04/21/2010, SSI= 56.0



Συγκριτική απεικόνιση



OCΤ Οπτικού Νεύρου



Optic
Disc

Retina

Choroid

Sclera

Optic
Nerve



Results review

Nerve head analysis module

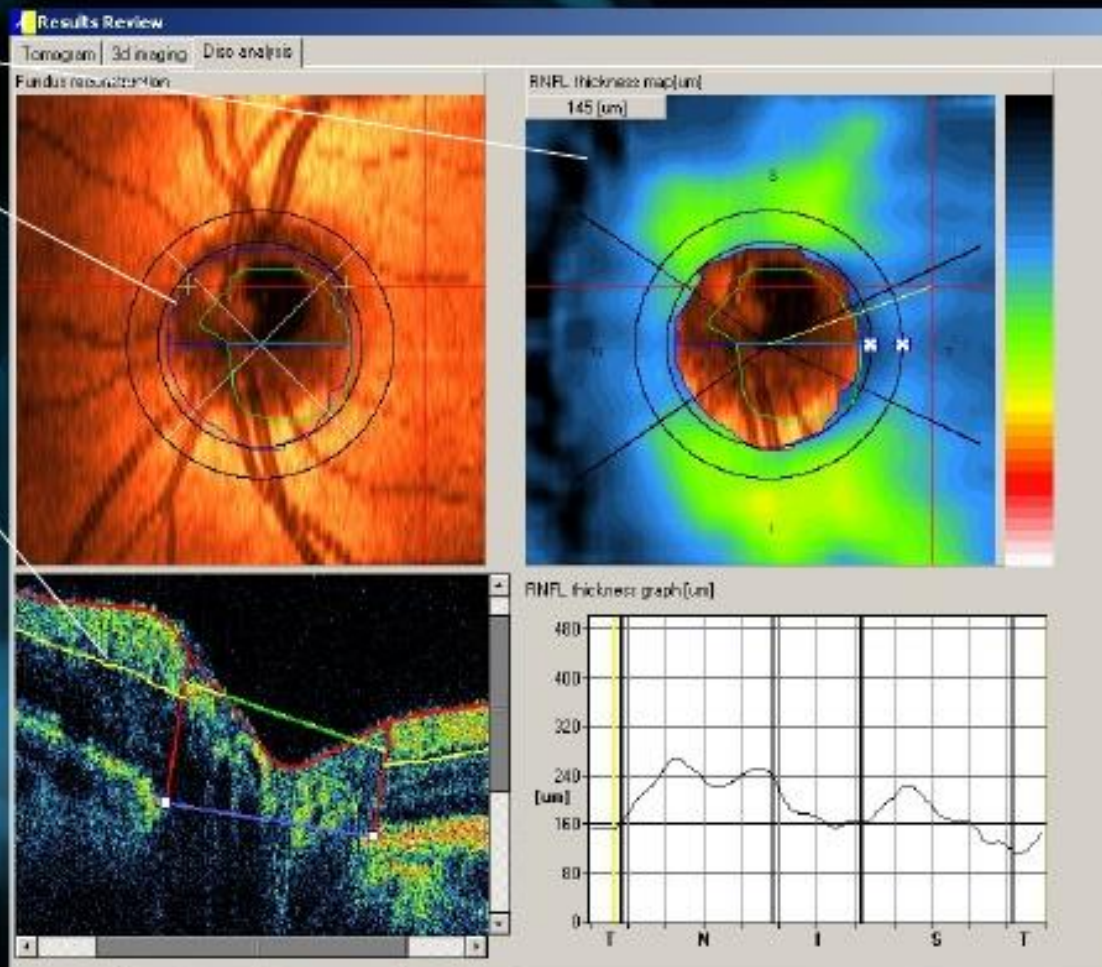
RNFL thickness map

Fundus reconstruction image

Disc marker (blue)
cup marker (green)

Retina cross section image

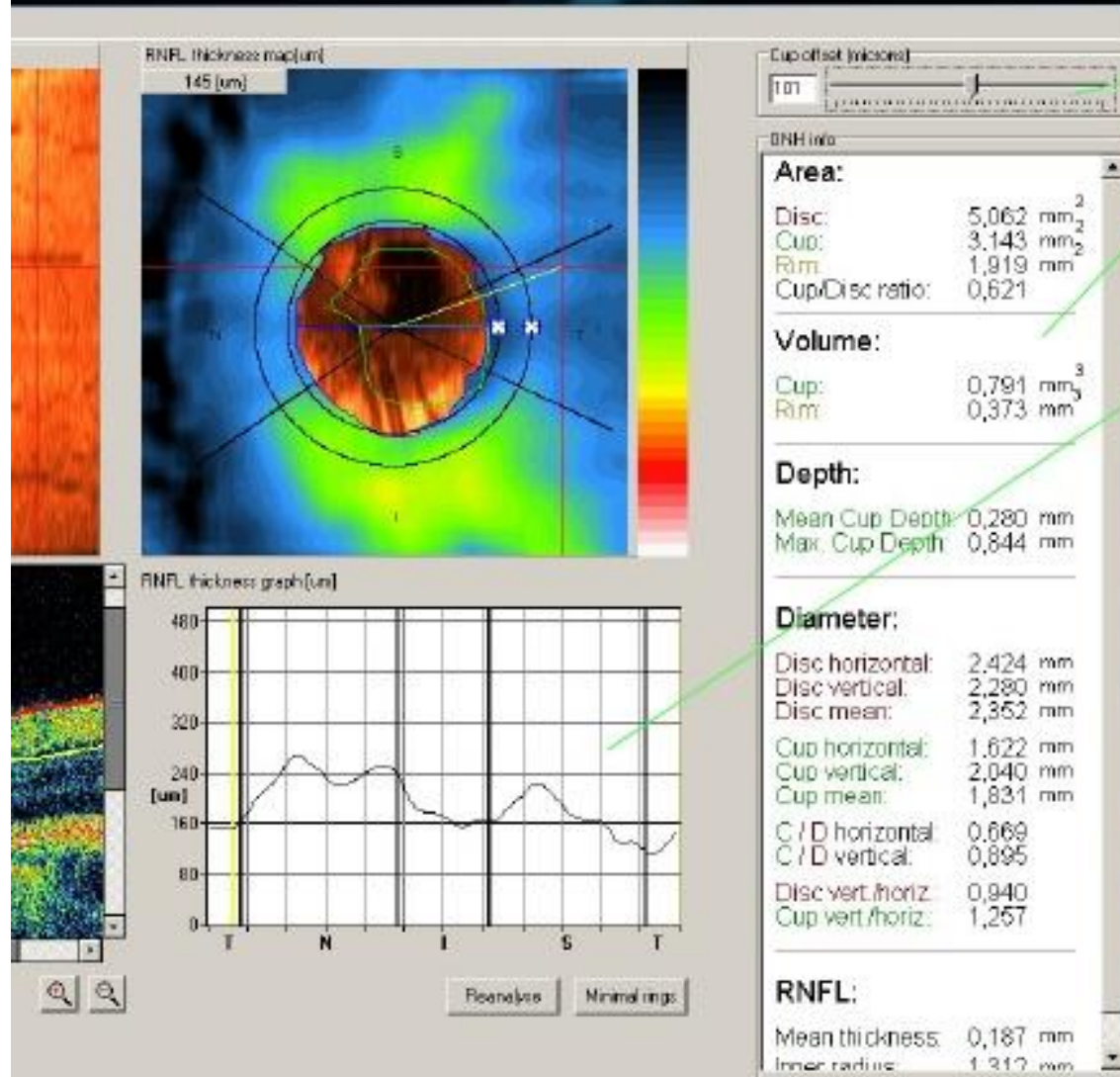
Disc marker (blue)
Cup marker (green)





Results review

Nerve head analysis module



Cup offset slider

Disc and Cup parameters panel

RNFL thickness graph around disc



Nerve head analysis module

Disc and cup parameters

DNH info	
Area:	
Disc:	5,062 mm ²
Cup:	3,143 mm ²
Rim:	1,919 mm ²
Cup/Disc ratio:	0,621
Volume:	
Cup:	0,791 mm ³
Rim:	0,373 mm ³
Depth:	
Mean Cup Depth:	0,280 mm
Max. Cup Depth:	0,844 mm
Diameter:	
Disc horizontal:	2,424 mm
Disc vertical:	2,280 mm
Disc mean:	2,352 mm
Cup horizontal:	1,622 mm
Cup vertical:	2,040 mm
Cup mean:	1,831 mm
C / D horizontal:	0,669
C / D vertical:	0,895
Disc vert./horiz.:	0,940
Cup vert./horiz.:	1,257
RNFL:	
Mean thickness:	0,187 mm
Inner radius:	1,312 mm

Disc area – measured along green line plane

Cup area – measured along white line plane

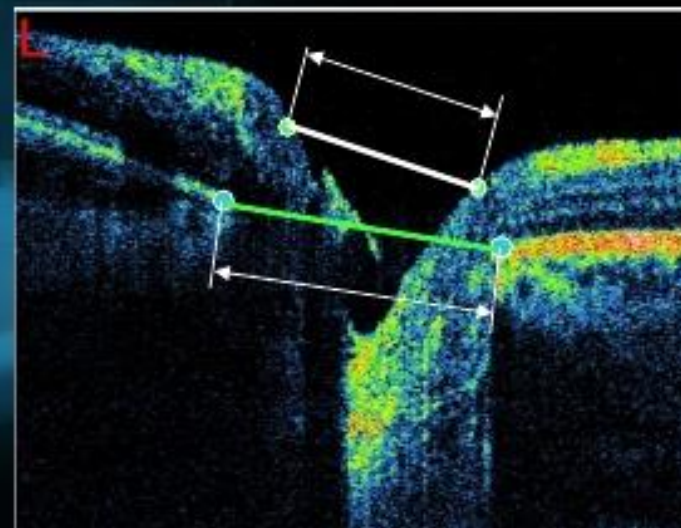
Rim area = Disc area – Cup area

Advantages of this method:

measured values

are independent

of tilt of scans





Nerve head analysis module

Disc and cup parameters

DNH info	
Area:	
Disc:	5,062 mm ²
Cup:	3,143 mm ²
Rim:	1,919 mm
Cup/Disc ratio:	0,621
Volume:	
Cup:	0,791 mm ³
Rim:	0,373 mm
Depth:	
Mean Cup Depth:	0,280 mm
Max. Cup Depth:	0,844 mm
Diameter:	
Disc horizontal:	2,424 mm
Disc vertical:	2,280 mm
Disc mean:	2,352 mm
Cup horizontal:	1,622 mm
Cup vertical:	2,040 mm
Cup mean:	1,831 mm
C / D horizontal:	0,669
C / D vertical:	0,895
Disc vert./horiz.:	0,940
Cup vert./horiz.:	1,257
RNFL:	
Mean thickness:	0,187 mm
Inner radius:	1,312 mm

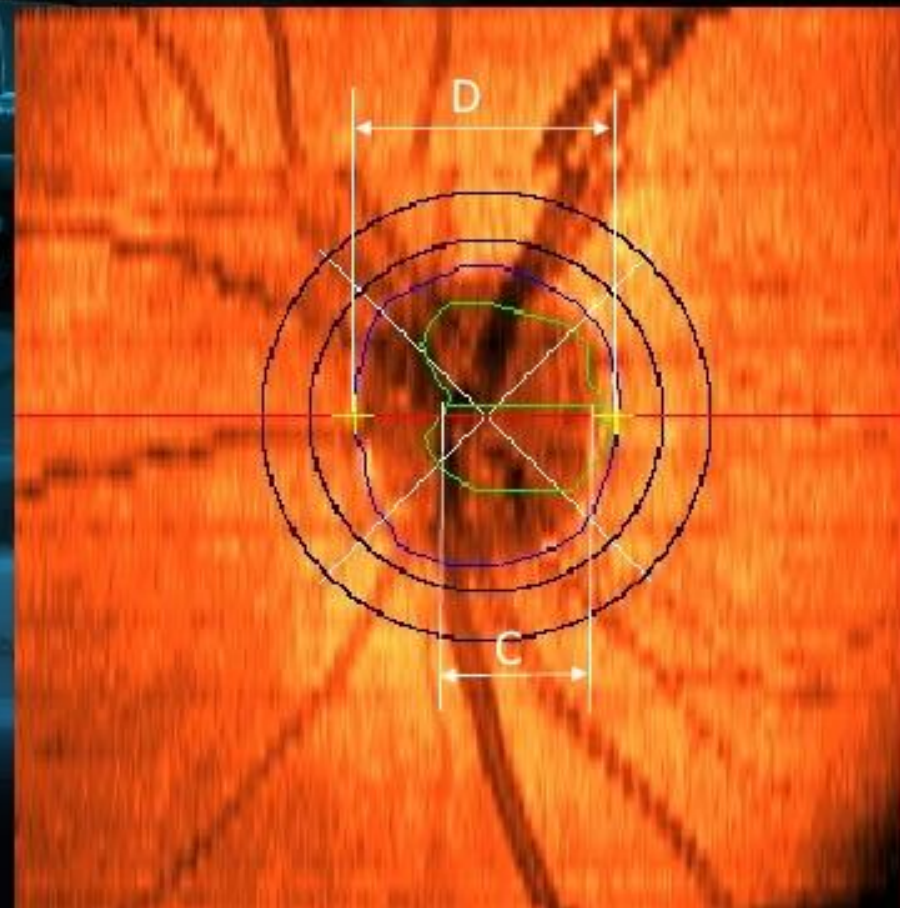
Diameters

-Horizontal Disk

diameter (D)

-Horizontal Cup

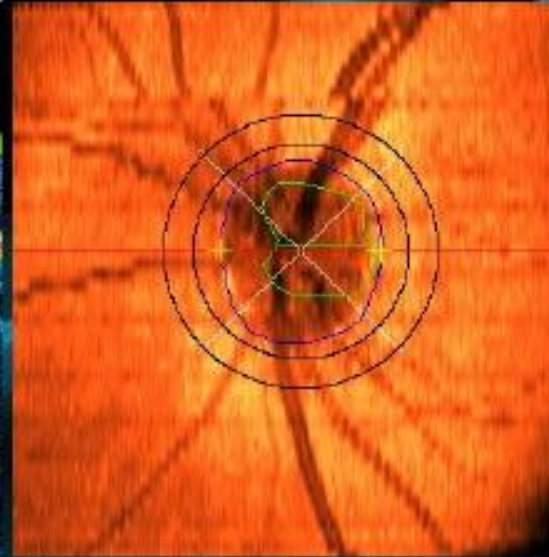
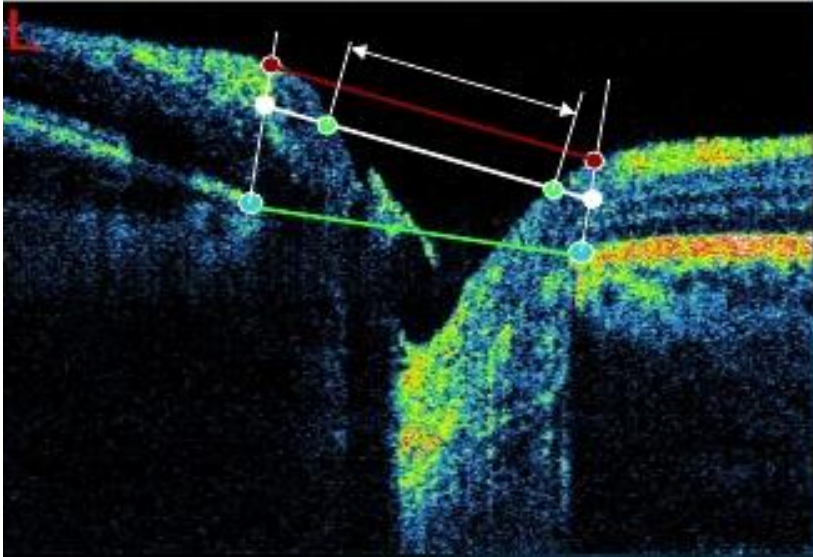
diameter (C)




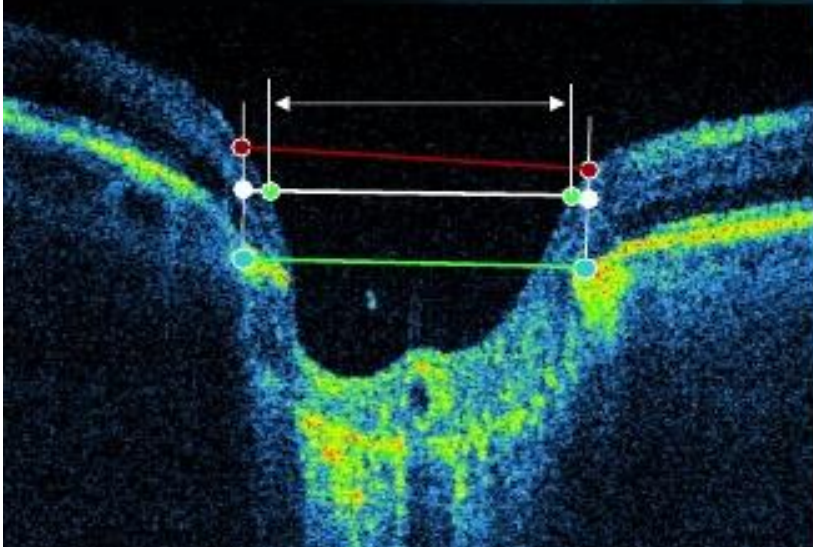


Nerve head analysis module

Cup to disk ratio

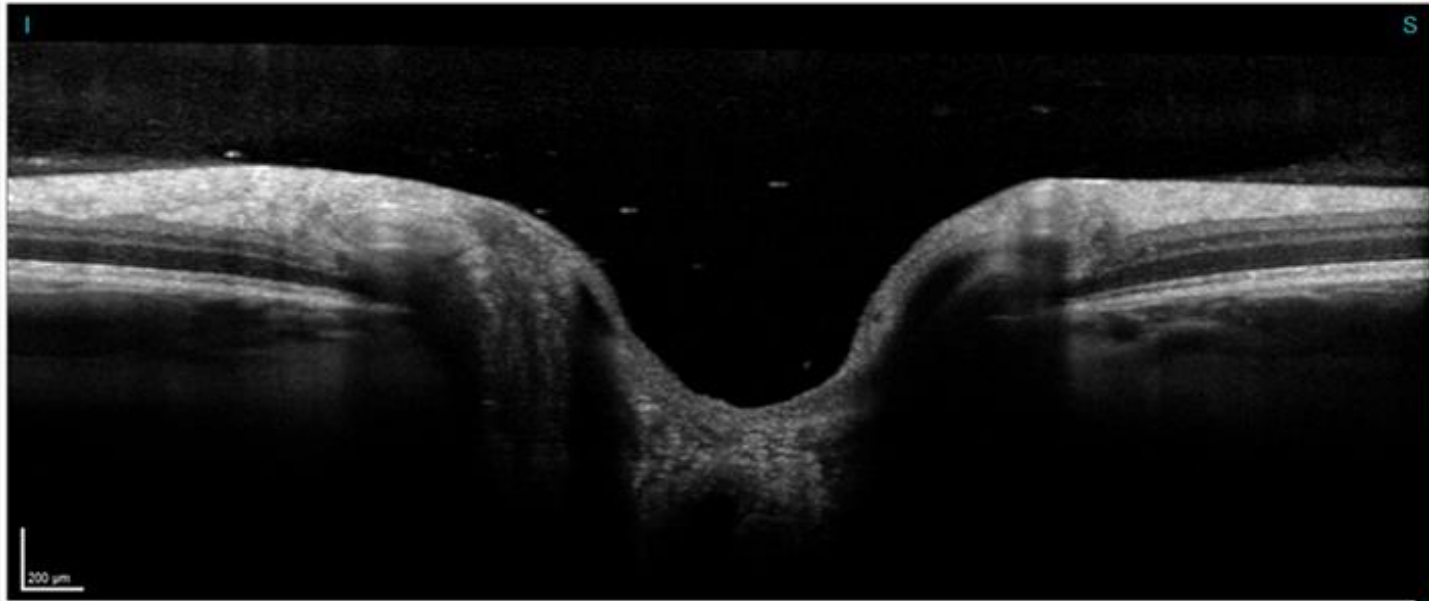
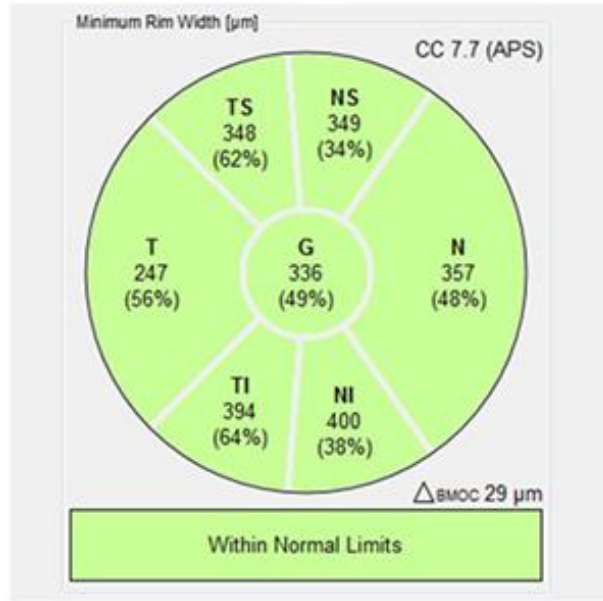


Normal

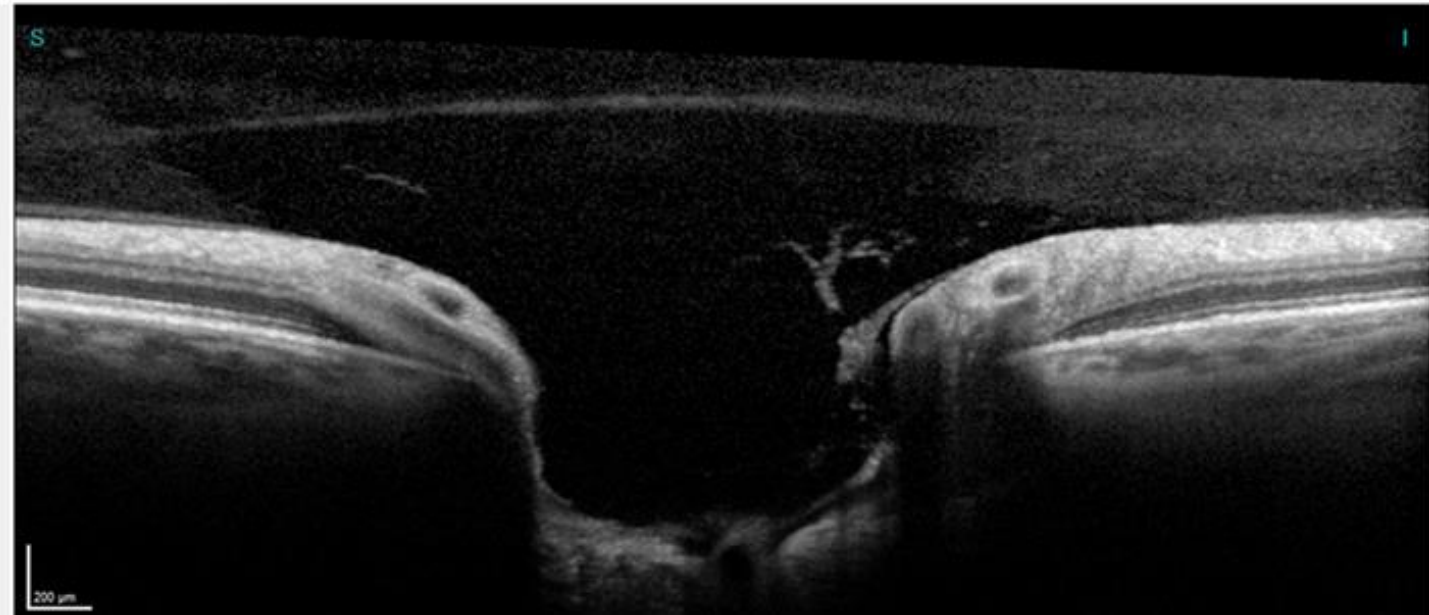
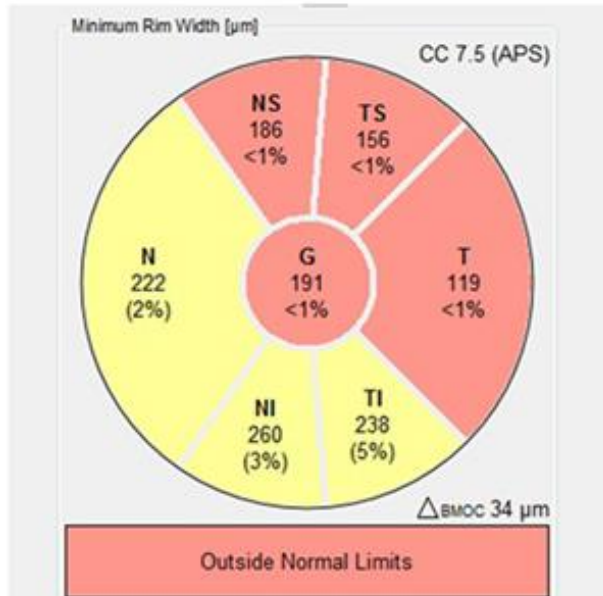


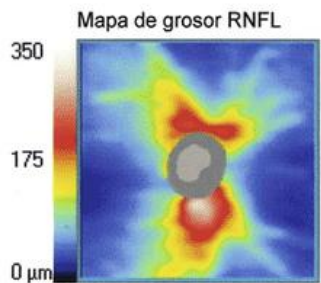
Glaucoma

Healthy optic nerve head

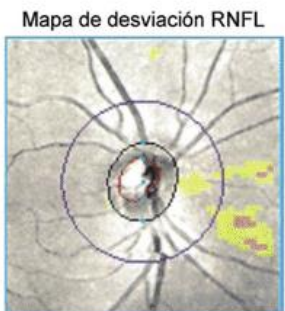
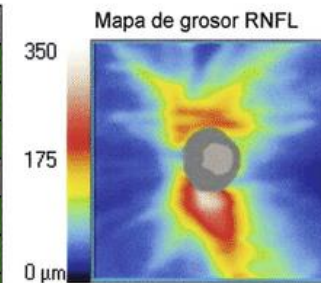


Optic nerve head with changes

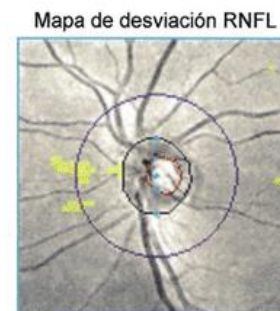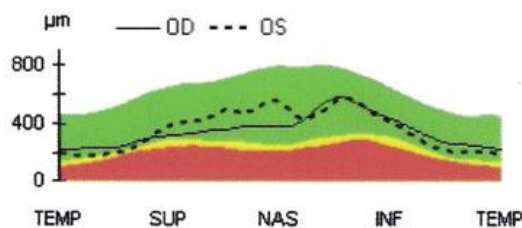




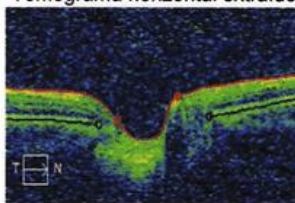
	OD	OS
Grosor RNFL promedio	97 μm	96 μm
Simetría RNFL	89%	
Área del borde	1,38 mm^2	1,38 mm^2
Área de disco	1,99 mm^2	1,88 mm^2
Proporción de C/D promedio	0,55	0,51
Proporción C/D vertical	0,55	0,47
Volúmen de la copa	0,152 mm^3	0,125 mm^3



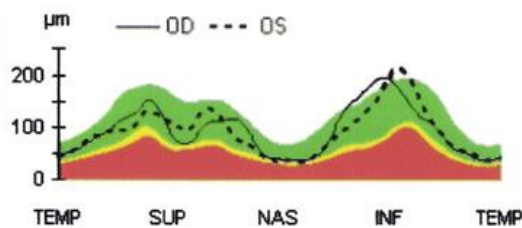
Grosor del borde neuroretinal



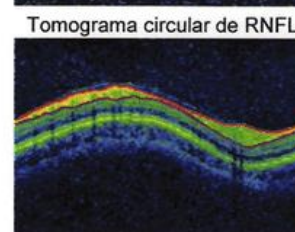
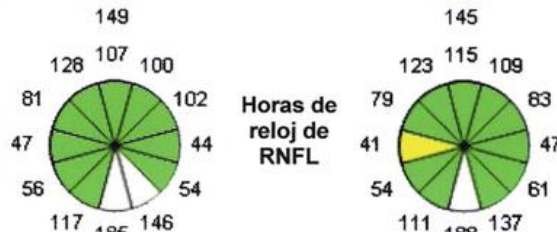

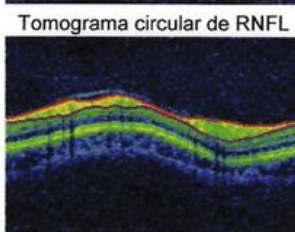
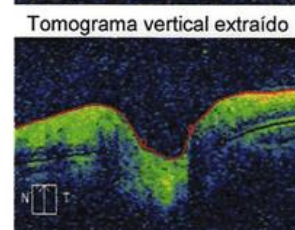
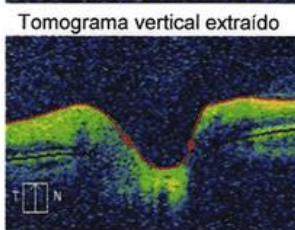
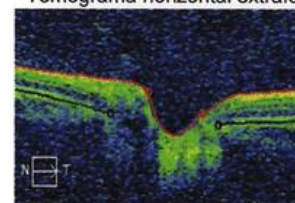
Centro del disco(-0,06,-0,09)mm
Tomograma horizontal extraído



Grosor RNFL



Centro del disco(-0,03,0,06)mm
Tomograma horizontal extraído



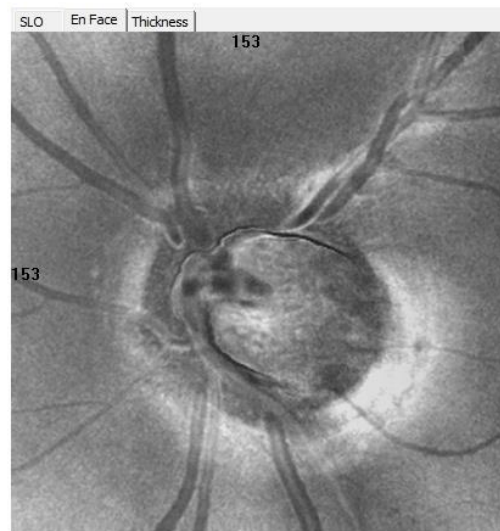
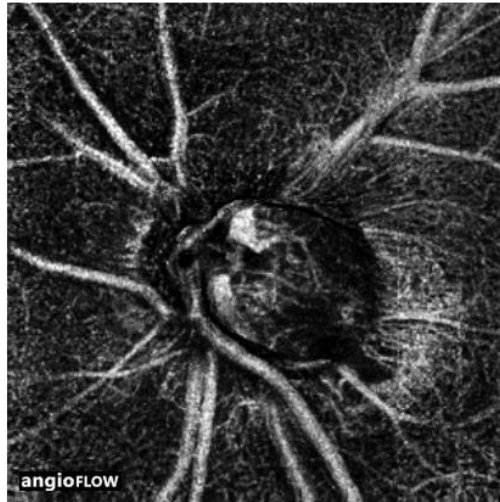
ANGIO OCT O.N.

Angio Disc

<http://www.oct-optovue.com>

Signal Strength Index 48

Left / OS



Save Settings

Restore Settings

Reference
 Nerve Head
 Vitreous
 RPC
 Choroid/Disc

Upper - ILM
Offset(um)
143 ...

Lower - ILM
Offset(um)
243 ...

3.00 x 3.00 Scan Size (mm)

3D Display

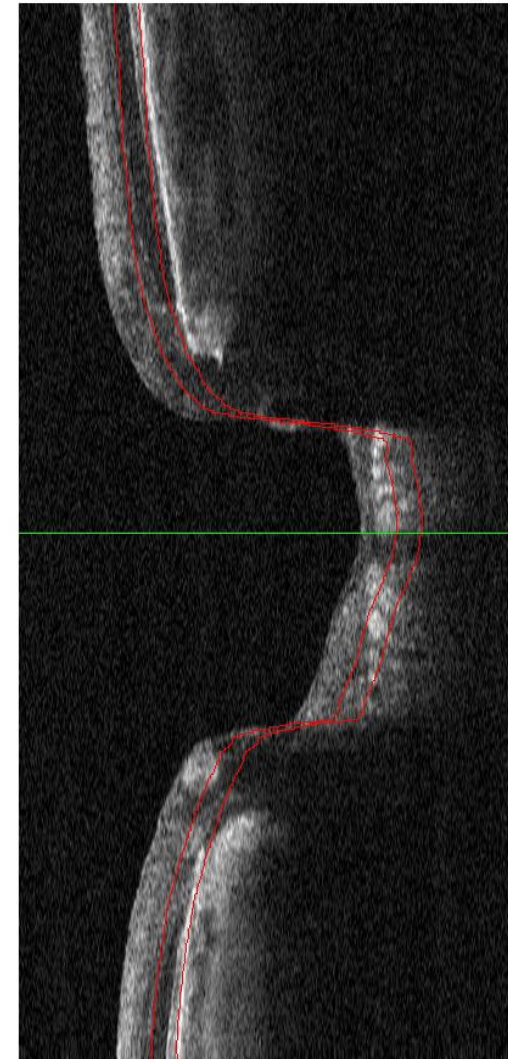
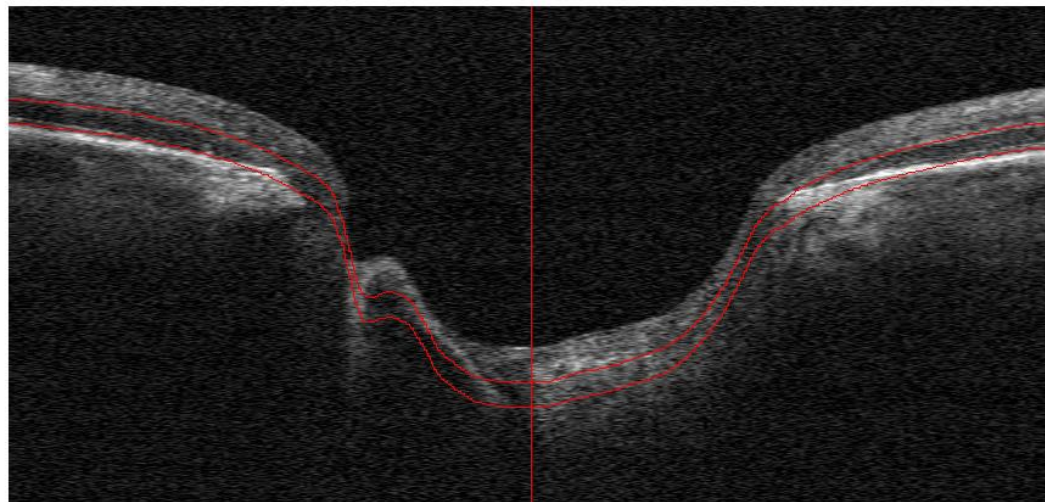
OverVue

Play

Show Bnd
 No MCT

Color
 Show Line

Flatten Bnd



Print

Comment

optovue

