

FEATURE ARTICLE ON LINE

Current Treatment of Age-Related Macular Degeneration

MARCO ZARBIN, MD, PhD, and BERNARD SZIRTH, PhD

Institute of Ophthalmology and Visual Science, New Jersey Medical School, Newark, New Jersey

ABSTRACT

Purpose. To review proved and experimental treatments for exudative and nonexudative complications of age-related macular degeneration (AMD), to consider the impact of current therapy on the structure of future clinical trials, and to consider the role of improved diagnostic imaging techniques on the effectiveness of current therapy as well as the structure of future clinical trials in AMD patients.

Results. Defining the cell biology of choroidal new vessel (CNV) formation and geographic atrophy will lead to identification of different biochemical pathways that are the target of AMD treatment. Many treatments and treatment combinations are under study for AMD, but all work through a finite number of pathways. Currently, the most effective proved therapy for AMD-associated CNVs is administered by repeated intravitreal injection of agents that inhibit vascular endothelial growth factor, e.g., ranibizumab. Improved drug delivery will enhance patient satisfaction and possibly will enhance the effectiveness and reduce the risk of current pharmacotherapy for AMD-associated CNVs. Combination therapy (e.g., verteporfin-photodynamic therapy + ranibizumab) appears to reduce the risk and enhance the effectiveness of CNV treatment compared with monotherapy with currently available agents. Improved noninvasive diagnostic imaging may lead to better visual outcomes with existing therapeutic modalities. Improved imaging also may alter favorably the design of future clinical trials for AMD-associated CNVs and thus reduce cost and increase the diversity of sight-saving treatments.

Conclusions. Delineation of the biochemical basis for CNV formation has led to development of pathway-based pharmacotherapy for AMD patients. Areas of investigation that will advance the field further include combination therapy, improved drug delivery, and improved noninvasive, high-resolution diagnostic imaging. The logistics of future clinical trials will be complicated by the need for an active treatment control group, more stringent definition of successful treatment, and the increased numbers of patients required for combination therapy studies.

(Optom Vis Sci 2007;84:E559-E572)

Key Words: age-related macular degeneration, choroidal neovascularization, geographic atrophy, pharmacology, ocular imaging, clinical trials

Age-related macular degeneration (AMD) is a condition characterized by the accumulation of membranous debris on both sides of the retinal pigment epithelium (RPE) basement membrane, with clinical manifestations of drusen, atrophy of the RPE and choriocapillaris, RPE detachment, and choroidal new vessel (CNV) formation with onset after 50 years of age.¹⁻⁵ It is the leading cause of blindness in the United States, and its prevalence is increasing.^{1,3} We will review treatment options for patients with AMD and also discuss how the results of current therapy may influence the development and testing of treatments in the future.

Prophylactic Therapy

The Age-Related Eye Disease Study (AREDS) demonstrated that vitamin and mineral supplementation can reduce the risk of

moderate visual loss among some patients with AMD.⁶ If patients had extensive intermediate-size drusen, noncentral geographic atrophy in one or both eyes, advanced AMD in one eye, or vision loss in one eye due to AMD and if they received daily supplementation with vitamin C (500 mg), vitamin E (400 IU), zinc oxide (80 mg), cupric oxide (2 mg), and β -carotene (15 mg), then the risk of at least moderate visual loss was reduced from 29% to 23% and the risk of developing advanced AMD (i.e., subfoveal atrophy or CNVs) was reduced from 28% to 20%. AREDS II (<http://www.areds2.org>) is a randomized multicenter clinical trial that will assess the role of lutein (10 mg)/zeaxanthin (2 mg) and ω -3 long-chain polyunsaturated fatty acids in the prevention of geographic atrophy or CNVs as well as the deletion of β -carotene and lowering the daily dose of zinc to 25 mg.

Proved Therapy for Choroidal New Vessels

Destructive Therapy

Laser Photocoagulation. The Macular Laser Photocoagulation Study demonstrated that photocoagulation of well-defined extrafoveal CNVs is effective in reducing the risk of visual loss in patients with AMD.⁷ The main benefit of treatment is observed during the first 18 months after surgery, with 41% of patients in the observation group experiencing ≥ 6 -line visual loss compared with 24% in the laser photocoagulation cohort (Fig. 1). Subsequently, the treatment benefit lessens primarily because of recurrent, subfoveal CNV growth in approximately 50% of patients during the first 5 years after surgery. Laser photocoagulation remains a treatment option for patients with well-defined extrafoveal CNVs, although they comprise a minority of those with AMD-associated CNVs.^{8,9}

Photodynamic Therapy. Visudyne (verteporfin), composed of benzoporphyrin derivative monoacid, circulates and complexes with low-density lipoproteins. Visudyne accumulates in neovascular tissue, which is rich in low-density-lipoprotein receptors.¹⁰ Nonthermal laser (689 nm) activation of verteporfin induces reactive oxygen species formation, endothelial damage with thrombus formation, and vascular occlusion.¹¹ Photodynamic therapy (PDT) of experimental CNVs with verteporfin is associated with relative sparing of the retina.¹⁰ (Retinal protection can be enhanced during verteporfin-PDT by the use of neurotrophic factors.^{12,13}) Verteporfin-PDT reduces the rate of visual loss in AMD patients with subfoveal CNVs compared with sham-treated controls. At 2-years follow-up, the mean change in visual acuity is -2.3 lines with Visudyne treatment vs. -4.5 lines among placebo-treated AMD patients with predominantly classic subfoveal CNVs.¹⁴ Verteporfin-PDT is palliative, with only approximately 9% of patients experiencing moderate visual gain at 2-years follow-up.¹⁵ The typical patient requires five to six treatment sessions

during the first 2 years of treatment. With verteporfin-PDT, there is an approximate 1% to 5% chance of ≥ 4 -line visual loss within 7 days of treatment.

Pathway-Based Therapy

Angiogenesis is a multistep process involving angiogenic factor production and release, binding of angiogenic factors to endothelial cells, and intracellular signaling followed by complex changes, including alteration in the extracellular matrix, cell proliferation and migration, and association with other cells (Fig. 2). Many different stimulators and inhibitors of ocular neovascularization have been identified (summarized in Ref. 2). Vascular endothelial growth factor (VEGF)-A is a mitogen and a survival factor for endothelial cells.¹⁶ It also serves as a chemotactic factor and enhances vascular permeability. VEGF-A is a homodimeric glycoprotein [molecular weight (MW), 45,000 Da]. Multiple VEGF-A isoforms of different amino acid length are generated by alternative mRNA splicing.^{16,17} The three major isoforms are VEGF₁₂₁, VEGF₁₆₅, and VEGF₁₈₉. VEGF₂₀₆, VEGF₁₈₉, and VEGF₁₆₅ have heparin-binding domains. VEGF₂₀₆ and VEGF₁₈₉ are sequestered in the extracellular matrix. VEGF₁₂₁ is a highly diffusible isoform. Plasmin can cleave VEGF₁₆₅ and generate VEGF₁₁₀, a biologically active amino-terminal fragment lacking the heparin-binding domain.^{18–20} Matrix metalloproteinase-3 cleaves VEGF₁₆₅ in the carboxy-terminus, which results in the production of VEGF₁₁₃, a biologically active peptide that does not bind heparin.²¹

VEGF-A exerts its biological effects by binding to two cell surface receptors, VEGF receptor-1 (VEGFR-1) and VEGF receptor-2 (VEGFR-2).¹⁶ These proteins are tyrosine kinases, and agonist binding results in phosphorylation of intracellular proteins, which initiates a cascade of intracellular signaling. VEGFR-2 is probably the major mediator of VEGF-A-induced endothelial cell proliferation, survival, angiogenesis, and increased vascular permeability.¹⁶

Pegaptanib (Macugen). Pegaptanib is an aptamer, i.e., an oligonucleotide that binds with very high affinity and high specificity. Pegaptanib binds within the heparin-binding domain of VEGF-A and thus binds VEGF₂₀₆, VEGF₁₈₉, and VEGF₁₆₅. It does not bind to the biologically active isoforms, VEGF₁₂₁, VEGF₁₁₃, and VEGF₁₁₀. In randomized multicenter studies, patients who received 0.3 mg pegaptanib intravitreally every 6 weeks for 1 year had a 70% chance of losing < 3 lines of vision as compared with 55% in the control group ($p < 0.0001$). Macugen therapy is palliative, with the main benefit being reduction in the severity of visual loss (Fig. 3).²² The likelihood of at least moderate visual improvement is approximately 5%, which is not significantly different from that of control. Approximately 1% of patients who received intravitreal pegaptanib developed endophthalmitis, and a comparable percentage developed retinal detachment or traumatic cataract.

Ranibizumab (Lucentis). Ranibizumab is a humanized anti-VEGF-A recombinant Fab fragment that has been affinity-matured to increase its binding affinity for VEGF-A. In contrast to pegaptanib, ranibizumab binds within the VEGFR-binding domain of VEGF-A. Thus, ranibizumab binds to VEGF₂₀₆, VEGF₁₈₉, VEGF₁₆₅, VEGF₁₂₁, VEGF₁₁₃, and VEGF₁₁₀, i.e., to all the biologically active isoforms of VEGF-A. Two randomized, double-masked, pivotal phase III clinical trials have demonstrated that monthly intravitreal

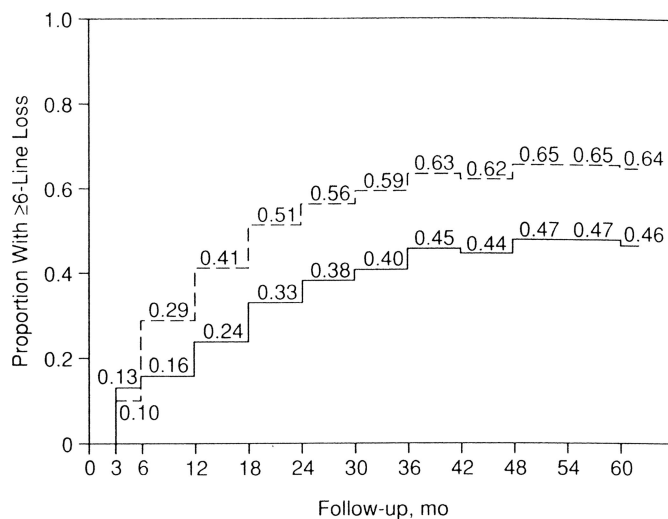


FIGURE 1.

Laser photocoagulation of well-defined extrafoveal choroidal new vessels in AMD: 5-year visual results.⁷ The solid line represents the proportion of laser-treated eyes that lost ≥ 6 -lines of visual acuity, whereas the dashed line shows the proportion of untreated eyes that lost ≥ 6 -lines of vision. Reproduced with permission from Arch Ophthalmol, 109, 1109–14, 1991.

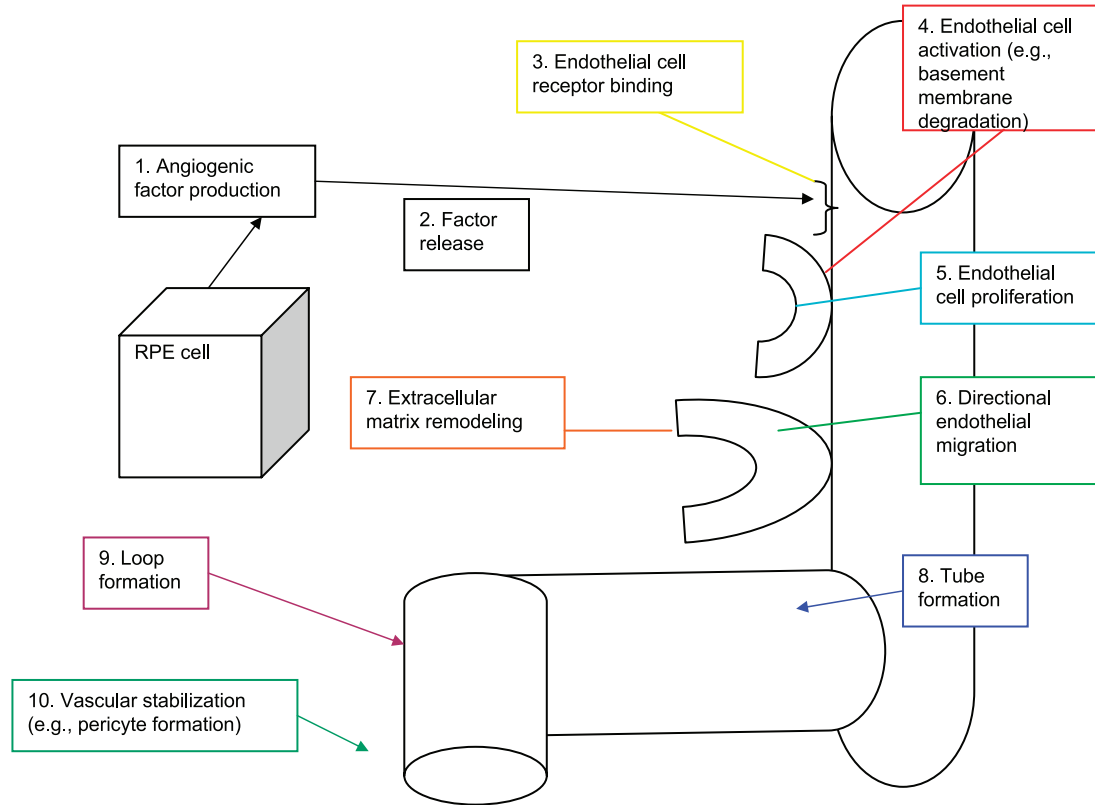


FIGURE 2. Angiogenesis is a multistep process. Please see text for details. A color version of this figure is available online at www.optvissci.com.

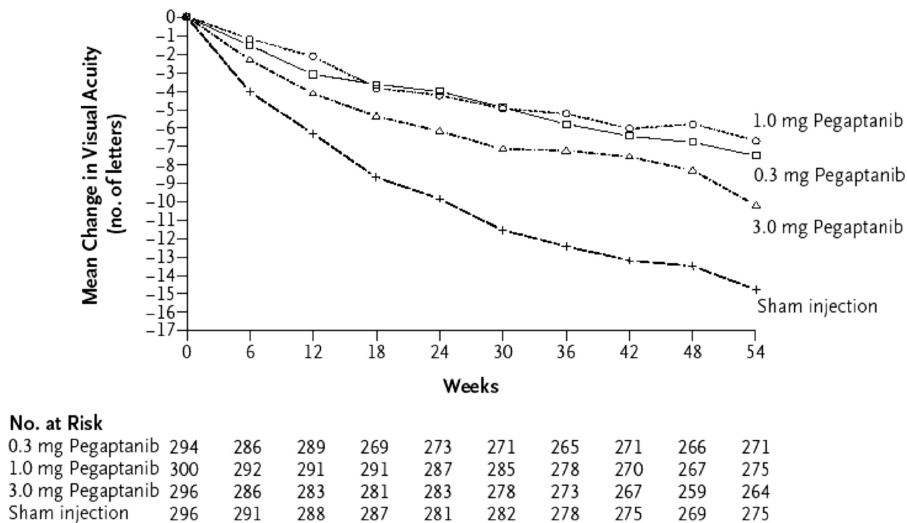


FIGURE 3. Visual outcome with pegaptanib (Macugen) vs. sham-injected controls.²² The graph represents the mean change in visual acuity as a function of time after enrollment for each patient cohort (i.e., sham injection, 0.3 mg pegaptanib, 1.0 mg pegaptanib, and 3.0 mg pegaptanib). Reproduced with permission from *N Engl J Med*, 351, 2805–16, 2004.

injection of ranibizumab is effective treatment for subfoveal CNVs in AMD patients.^{23,24}

The MARINA study assessed the response of minimally classic or occult CNVs to ranibizumab.²³ Patients (n = 716) were assigned randomly to receive sham injection (n = 238), 0.3 mg ranibizumab (n = 238), or 0.5 mg (n = 240) ranibizumab. At 24 months follow-up, approximately 90% of ranibizumab-treated pa-

tients had lost <15 letters on the Bailey-Lovie chart as compared with 53% of the sham-injected patients. This treatment response was independent of lesion size, initial visual acuity, or whether the lesion was a minimally classic vs. occult with no classic CNV. Most importantly, approximately 33% of patients receiving 0.5 mg ranibizumab experienced at least 15 letters visual improvement by 24 months follow-up vs. 4% in the sham-injected patients (Fig. 4).

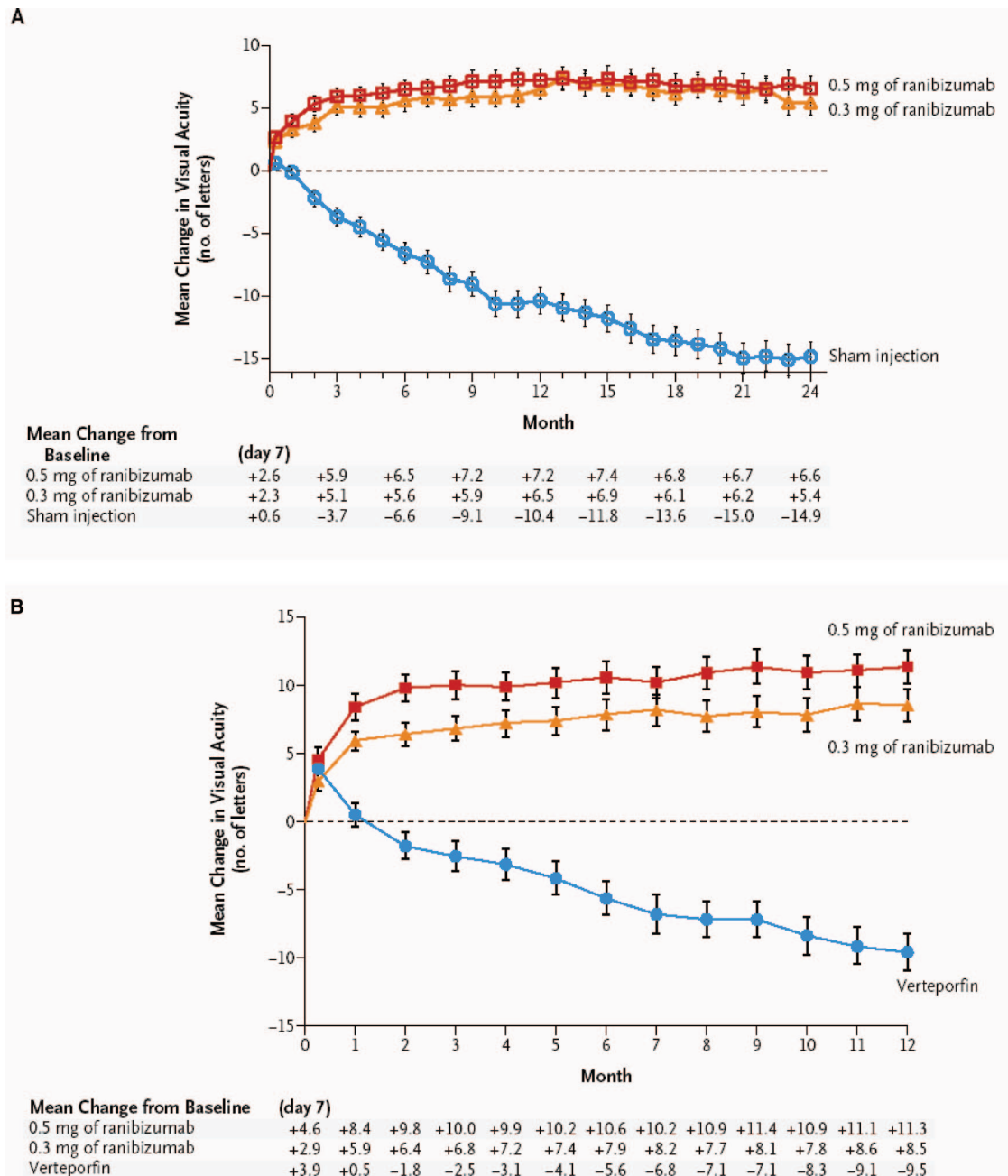


FIGURE 4. Visual outcome with ranibizumab (Lucentis).²⁴ A, The MARINA trial assessed treatment response in patients with minimally classic or occult with no classic subfoveal CNVs. B, The ANCHOR trial assessed treatment response in patients with predominantly classic (i.e., 50% or more of the lesion comprised classic CNV) subfoveal CNVs. Reproduced with permission. A color version of this figure is available online at www.optvissci.com.

The risk of endophthalmitis among patients receiving intravitreal ranibizumab was approximately 1%. The risk of cataract was approximately 0.2%. There were no cases of retinal detachment among patients receiving intravitreal therapy. Owing to the anti-VEGF activity of ranibizumab, there is a theoretical risk of systemic complications such as hypertension, myocardial infarction, and stroke. There was no imbalance among treated and control groups regarding hypertension. The risk of myocardial infarction among sham-injected, 0.3 mg ranibizumab-injected, and 0.5 mg ranibizumab-injected cohorts was 1.7%, 2.5%, and 1.3%, respectively. The risk of stroke among the three groups was 0.8%, 1.3%, and 2.5%, respectively. The risk of nonocular hemorrhage was

5.5%, 9.2%, and 8.8% in the three cohorts, respectively. These differences were not statistically significant.

The ANCHOR study assessed the response of predominantly classic CNVs.²⁴ Patients (n = 423) were randomly assigned to receive verteporfin-PDT plus sham injection (n = 143) or sham PDT plus injection of either 0.3 mg (n = 140) or 0.5 mg (n = 140) ranibizumab. At 12-months follow-up, approximately 95% of ranibizumab-treated patients lost <15 letters of vision as compared with 64% in the Visudyne active treatment control group. Among patients treated with 0.5 mg ranibizumab, 40% gained at least 15 letters vision vs. 6% in the Visudyne treatment cohort. Among ranibizumab-injected patients, there was an approximate

1% risk of endophthalmitis. Retinal detachment was observed in one patient in both the Visudyne (0.7%) and 0.3 mg ranibizumab (0.7%) cohorts. There were no cases of lens injury. The risk of hypertension was the same in all cohorts. The risk of myocardial infarction among Visudyne, 0.3 mg ranibizumab, and 0.5 mg ranibizumab cohorts was 0.7%, 0.7%, and 2.1%, respectively. The risk of stroke or cerebral infarction was 0.7% in each of the three cohorts. The risk of nonocular hemorrhage was 2.1%, 5.1%, and 6.4% in each of the three cohorts. Immunoreactivity to ranibizumab before treatment was 1.5%, 3.2%, and 0.8% among the Visudyne, 0.3 mg ranibizumab, and 0.5 mg ranibizumab cohorts, respectively. After 12 months of treatment, immunoreactivity was present in 1.6%, 1.6%, and 3.9% of patients in each of these cohorts, respectively. The potential consequence of immunoreactivity is that patients who develop an immune response might exhibit increased intraocular inflammation after intravitreal injection and possibly might not respond to the medication as well as patients who do not exhibit such a response. In practice we have not observed this phenomenon.

In both the MARINA and ANCHOR trials, visual acuity improvement appeared to reach a plateau by the 4-months time point (Fig. 4). Monthly injections are inconvenient, entail risk, and are expensive. The PIER study provides useful information in this regard (<http://www.gene.com/gene/news/press-releases/display.do?method=detail&id=9037>). In this trial, patients with subfoveal CNVs were randomly assigned to sham injection ($n = 63$), 0.3 mg ranibizumab ($n = 60$), or 0.5 mg ranibizumab ($n = 61$). Patients received sham or ranibizumab injections every 4 weeks for three doses followed by additional treatment every 3 months. The ranibizumab-treated patients showed an improvement in mean visual acuity during the first 3 months of the study, but this improvement was not sustained. Nonetheless, 0.5 mg ranibizumab cohort had a mean visual acuity change that was 16 letters better than that of the sham cohort by month 12 ($p < 0.0001$). Thus, it appears that injecting patients with ranibizumab every 3 months (after an induction phase of three monthly injections) does not produce the same chance for visual benefit as monthly injection, at least during the first 12 months of therapy.

In the PRONTO (Prospective OCT Imaging of Patients with Neovascular AMD Treated with Intravitreal Lucentis) study, patients ($n = 40$) received 0.5 mg ranibizumab at entry, month 1, and month 2.²⁵ Optical coherence tomography (OCT) measurements were obtained at baseline and at least monthly after injection (more frequently during the first 2 months after entry). Fluorescein angiograms were obtained at baseline and every 3 months thereafter. Retreatment with ranibizumab was done only if one or more of the following conditions were obtained: (1) OCT central thickness increased 100 μm , (2) ≥ 5 letter visual loss associated with subretinal fluid (as judged with OCT), (3) new onset classic CNV, (4) new macular hemorrhage, (5) persistent subretinal or intraretinal fluid was present 1 month after the previous injection. One day after the first injection, there was a decrease in the mean OCT thickness of 47 μm . By month 12, the mean visual acuity improved by 9.3 letters ($p < 0.001$), and the mean central thickness decreased by 178 μm compared with baseline ($p < 0.001$). Mean visual acuity improvement was 9.3 letters, and the mean central thickness had decreased by 178 μm . The average number of injections over the first year was 5.6. Visual acuity improved

≥ 15 letters in 35% of patients, and once macular fluid resorbed completely, the mean interval before another injection was 4.5 months.

Although the risk of arterial thromboembolic events was not increased significantly among ranibizumab-treated patients in these phase III studies (overall risk $\sim 2.1\%$ in ranibizumab-treated patients during year 1 vs. $\sim 1.1\%$ among controls), the studies were not powered for statistical significance between the two different ranibizumab doses. Year 2 data from the MARINA study indicate the overall rate of antiplatelet trialists' collaboration (APTC)-defined arterial thromboembolic events, which includes nonfatal myocardial infarction, nonfatal stroke, and death from a vascular or unknown cause,²⁶ was 4.6%, 4.6%, and 3.8% among the 0.5 mg Lucentis, 0.3 mg Lucentis, and control cohorts, respectively. Year-2 data from the ANCHOR study indicate that the overall rate of APTC arterial thromboembolic events was 5%, 4.4%, and 4.2% in the 0.5 mg, 0.3 mg, and verteporfin-PDT cohorts, respectively. The SAILOR study is an ongoing phase IIIb study whose objectives are to evaluate the safety of 0.3 mg and 0.5 mg Lucentis in patients with AMD-associated subfoveal CNVs. In cohort 1 of this study, the dose is randomly assigned and is administered once a month for 3 months and thereafter as needed on the basis of retreatment criteria. Preliminary data from a planned interim safety analysis of these patients (average follow-up 230 days) show a higher incidence of stroke in the 0.5 mg cohort (1.2%) vs. the 0.3 mg cohort (0.3%) ($p = 0.02$). Patients with a history of stroke appeared to be at a higher risk for subsequent strokes. There were no statistically significant differences between the two Lucentis groups regarding the APTC arterial thromboembolic events of myocardial infarction or vascular death (Lucentis Dear Healthcare Provider Letter January 24, 2007; available at <http://www.gene.com/gene/products/information/tgr/lucentis/index.jsp>).

Bevacizumab (Avastin). Both ranibizumab and bevacizumab are derived from a mouse monoclonal antibody directed against VEGF-A.²⁷ Ranibizumab is a humanized, affinity-matured, Fab fragment (MW ~ 48 kDa). Bevacizumab is a glycosylated, humanized Fab fragment coupled to an Fc fragment (MW ~ 149 kDa). The half-life of ranibizumab is probably shorter than that of bevacizumab. In experimental systems, ranibizumab is approximately 20-fold more potent in blocking VEGF-A-stimulated endothelial cell proliferation, although both ranibizumab and bevacizumab bind all forms of VEGF-A. The presence of the Fc fragment might render bevacizumab recipients more susceptible to development of an immune response to the therapy. The larger size of bevacizumab might promote longer half-life within the eye, but since systemic absorption appears likely,²⁸ it might also increase the chance of systemic side effects compared with ranibizumab. After an initial report on the effectiveness of intravitreal bevacizumab by Philip Rosenfeld et al.,²⁹ several retrospective studies^{30–32} and one prospective nonrandomized study³³ demonstrated the effectiveness of intravitreal bevacizumab in treating AMD-associated subfoveal CNVs. Avastin is substantially cheaper to administer for intravitreal injection than Lucentis.²⁷ Overall, it appears likely that intravitreal bevacizumab and ranibizumab have comparable visual benefit for AMD patients with subfoveal CNVs. It remains to be seen whether the needed frequency

TABLE 1.

Some anti-angiogenic substances under development for treatment of CNVs

Name	Company	Mechanism	Comment
VEGF Trap	Regeneron Pharmaceuticals, Inc.	Binds free VEGF-A	Phase II clinical trial underway
Bevasiranib	Acuity Pharmaceuticals, Inc.	siRNA that targets VEGF mRNA	Phase II clinical trial completed
Sirna-027	Sirna Therapeutics, Inc.	siRNA that targets VEGF receptor mRNA	Phase II trial initiated
Vatalanib	Novartis	Inhibits VEGFR-1, -2, and -3	Phase I studies underway (combination therapy with verteporfin-PDT)
AG-013958	Pfizer	Inhibits VEGFR and PDGFR	Subtenon delivery
AL-39324	Alcon	Inhibits ATP binding to tyrosine kinase and retinal endothelial cell proliferation	Phase I studies underway
PEDF-adenoviral vector	GenVec, Inc.	Pigment epithelial derived factor (PEDF) is neurotrophic (vs. ranibizumab) and induces endothelial cell apoptosis	Prolonged delivery of anti-CNV agent at biologically relevant doses after a single injection Phase I trial underway

of re-injection and/or the risk of systemic side effects is comparable. A National Eye Institute-supported randomized study [Comparison of AMD Treatments Trial (CATT); Daniel Martin, MD, Principal Investigator] comparing intravitreal ranibizumab and bevacizumab for treatment of AMD-associated CNVs is underway.

Anecortave Acetate (Retaane). Anecortave acetate is an angiostatic cortisone, which is a cortisol structural analogue devoid of glucocorticoid activity. The compound is not anti-inflammatory. Retaane is anecortave acetate in depot suspension. Anecortave acetate inhibits lipopolysaccharide-induced corneal neovascularization. Retaane is delivered through an incision in Tenon's capsule with posterior juxtasceral delivery. This depot can maintain drug levels in the overlying choroid and retina for months. Phase II/III studies have shown that 15 mg Retaane reduces the risk of visual loss [79% with <3 log MAR lines change compared with 53% with placebo at 12 months follow-up ($p = 0.0323$)].^{34,35} A randomized study comparing Retaane ($n = 263$) and PDT ($n = 267$) showed that 45% of patients who received posterior juxtasceral Retaane at entry and at 6 months follow-up (plus sham PDT) had <3-line visual loss at 12 months follow-up vs. 49% in the cohort receiving PDT every 3 months (plus sham Retaane injection at entry and at month 6).³⁶ These differences were not statistically significant ($p = 0.43$), but the conditions for noninferiority were not met. (Noninferiority trials are intended to show that the effect of a new treatment is not worse than that of an active control by more than a specified margin. Noninferiority trials may be necessary if a placebo group cannot be included ethically.) In view of the competing alternatives, as a treatment for established CNVs, Retaane might best be considered as a component combination therapy (please see below) or as prophylactic therapy. The Alcon C02-60 trial will determine whether subtenon Retaane administered every 6 months to high-risk AMD eyes can reduce the chance of developing CNVs.

Future Treatments

Pathway-Based Pharmacotherapy: New Alternatives

As one might expect, treatments that interrupt different points along the pathway for new vessel formation are under development (Table 1).^{37,38} It is possible that these compounds will provide advantages over currently available therapy even if they interrupt the same biochemical pathway. For example, VEGF Trap is a high-affinity recombinant fusion protein in which the IgG domain 2 of VEGFR-1 and domain 3 of VEGFR-2 are fused to a crystallizable IgG Fc fragment.³⁹ This compound binds with very high affinity to and neutralizes all VEGF-A isoforms. (It also binds placental growth factor.) If VEGF Trap has a longer duration of action than ranibizumab, then the need for intravitreal injection might be reduced. VEGF Trap is effective in preclinical models, and phase II studies are underway. It may be of interest to note that VEGFR-1 occurs in a soluble (vs. membrane-bound) form. Soluble VEGFR-1 is thought to bind free VEGF-A, thus effectively functioning as a naturally occurring VEGF inhibitor.¹⁶ Another anti-VEGF therapy under development involves use of small interfering RNA (siRNA). In this approach, double-stranded RNA targets the mRNA-of-interest, resulting, ultimately, in silencing the expression of the targeted gene. siRNA inhibits choroidal neovascularization in a mouse model.⁴⁰ Bevasiranib is siRNA targeted against VEGF mRNA (Table 1) and is in early clinical studies for treatment of CNVs (<http://www.acuitypharma.com/press/release13.pdf>). Sirna-027 is modified siRNA that targets VEGFR-1 and is in early clinical studies (<http://www.sirna.com/wt/page/ocular>).⁴¹

Some putative therapies target VEGFR signal transduction. For example, tyrosine kinase inhibitors provide small molecule therapy that prevents VEGFR signal transduction (Table 1). It is not clear yet whether these compounds will act selectively on CNV growth, but they have some attractive features, e.g., the possibility of subtenon administration.

Gene therapy for CNVs is under development.⁴² Pigment epithelial derived factor induces endothelial cell apoptosis and, in contrast to ranibizumab, is neurotrophic. (Neurotrophic factors are proteins that promote neuronal survival, usually by inhibiting apoptosis, and may also induce differentiation of

neuronal progenitor cells.) Adenoviral vector-mediated pigment epithelial derived factor gene delivery to RPE cells provides a means of enhancing local production of this anti-angiogenic molecule at biologically relevant doses for a prolonged time after a single injection (Table 1).

Sustained Delivery

Because of the number of AMD patients with subfoveal CNVs who may benefit from therapy, one can anticipate that chronic treatment requiring intravitreal injections is not an ideal delivery approach. Even a 1% complication rate may be associated with thousands of endophthalmitis cases annually, and frequent office visits place onerous demands on patients' (and, often, family members') time. Sustained drug delivery systems are being developed. One approach, mentioned above, involves gene therapy, which has the potential to provide long-term delivery of anti-angiogenic molecules after a single surgical procedure. Another approach involves use of Macugen microspheres, 18- μ m-diameter spheres of pegaptanib conjugated to a polymer. The spheres can be injected into the vitreous cavity and, in preclinical studies, have a 6 months duration of action (Anthony Adamis, personal communication). Retisert implants (Bausch and Lomb) are Food and Drug Administration-approved for treatment of uveitis.⁴³ They deliver fluocinolone acetonide at a steady state rate of approximately 0.4 μ g/d for more than 2 years. Installation of the implant requires a sclerotomy and is done in the operating room. Complications include steroid-induced cataract and glaucoma (requiring glaucoma filtering surgery in ~6% of noninfectious posterior uveitis patients at 34 weeks follow-up,⁴³ with unpublished safety data in uveitis trials indicating a rate of ~30% at 2-year follow-up⁴³). These implants are under study for the treatment of AMD. Cell-based therapy might be the best approach to chronic therapy. Neurotech has developed plasmid-transfected RPE cells (NT-501) that produce ciliary neurotrophic factor. The cells are encapsulated in a polymer and implanted surgically into the vitreous cavity. The polymer pore size is such that inflammatory cells cannot gain access to the capsule's internal chamber, thus preventing immune rejection of the cells and also preventing cell migration into the vitreous cavity.⁴⁴ Phase III trials for nonexudative AMD and retinitis pigmentosa are underway. One might transfect cells to produce anti-angiogenic substances to treat the exudative manifestations of AMD.

Combination Therapy

Therapy involving combinations of therapeutic agents may reduce the need for repeated treatment with potentially toxic agents. (The long-term consequences of pan-VEGF-A inhibition in the eye, for example, are unknown, and there may be an increased risk of stroke, particularly in patients with a previous stroke history.) Combination therapy has been quite effective in infectious disease and cancer therapy. Sequential inhibition of folate metabolism pathway by trimethoprim and sulfamethoxazole (Bactrim) results in synergistic antibacterial effects. Combining an anti-VEGF agent and chemotherapy or radiation therapy results in a greater antitumor effect than that seen with either treatment alone.^{45,46} Vascular response to anti-VEGF therapy appears to be related to the degree of vessel maturity (e.g., presence of pericytes and smooth muscle cells around capillaries and larger vessels, respectively).^{47,48} Mural cell recruitment to endothelial cells requires platelet-derived growth factor (PDGF)-B and PDGF receptor- β signaling.⁴⁹

Tumor vessels lacking mural cells are more sensitive to VEGF-A withdrawal-induced apoptosis.⁴⁸ Thus, more mature vessels may be less sensitive to anti-VEGF-A therapy. In animal models of choroidal neovascularization, combined inhibition of VEGF-A and PDGF-B signaling pathways via pegaptanib and an antibody against PDGF receptor- β , respectively, synergistically inhibits CNV growth.⁵⁰

Combining different anti-CNV agents may have a synergistic effect leading to (1) better visual outcome; (2) reduced frequency of treatment [with attendant lower risk of adverse events (e.g., endophthalmitis) and greater patient convenience], and (3) less likelihood of "escape." Escape refers to the phenomenon in which cells (e.g., tumor cells) develop alternative pathways that allow them to overcome the iatrogenic inhibition of a pathway essential for their survival or growth. Results from some combination therapy trials are given below.

Verteporfin-PDT + Intravitreal Triamcinolone Acetonide. Corticosteroids are potent anti-angiogenic agents (Table 2). In addition, triamcinolone acetonide has antipermeability effects. Combination therapy with verteporfin-PDT and steroids was proposed first by Richard Spaide, MD. Several uncontrolled studies indicate that combined verteporfin-PDT and intravitreal triamcinolone acetonide injection is more effective than either treatment alone. Generally, these studies have shown that combination therapy results in a reduced need for repeated PDT and an increased chance for modest visual improvement (compared with PDT alone).⁶¹⁻⁶⁵ Significant complications can occur with this therapeutic combination, including cataract (in up to 57% of patients), glaucoma (in up to 40% of patients, sometimes requiring surgical intervention), and endophthalmitis (in ~1%). In the largest series published to date, Augustin and Schmidt-Erfurth⁶¹ reported a prospective, noncomparative interventional cases series of 184 AMD patients who underwent intravitreal injection of 25 mg triamcinolone 16 h after verteporfin-PDT. Median follow-up was 38.8 weeks (range, 12-103 weeks). Combined therapy was re-

TABLE 2.
Some anti-angiogenic effects of corticosteroids

Induce capillary basement membrane dissolution (in growing capillaries). ⁵²
Alter the behavior of inflammatory cells that stimulate angiogenesis. ⁵²⁻⁵⁴
Inhibit bFGF-stimulated choroidal endothelial cell migration and tube formation. ⁵⁵
Inhibit bFGF-induced activation of matrix metalloproteinase-2. ⁵⁵
Reduce oxidative stress-induced VEGF mRNA expression in ARPE-19 cells. ⁵⁶
Alter intercellular adhesion molecule expression of non-endothelial cells. ⁵⁷
Reduce blood-retinal barrier breakdown in rabbit eyes. ⁵⁸
Inhibit platelet-derived growth factor-induced vascular endothelial growth factor expression. ⁵⁹
Reduce numbers of microglia in AMD-associated choroidal new vessels. ⁶⁰

bFGF, basic fibroblast growth factor; VEGF, vascular endothelial growth factor.

Adapted with permission from Arch Ophthalmol, 124, 563-71, 2006.⁵¹

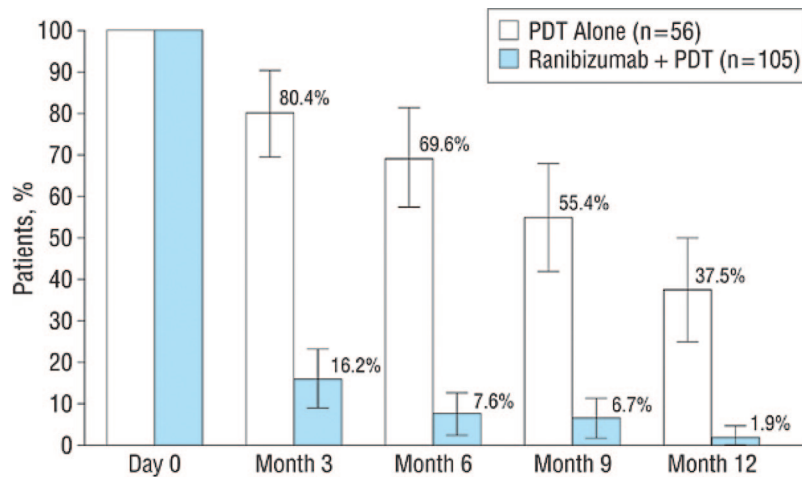


FIGURE 5.

FOCUS trial results.⁷⁰ Data are percentage of patients receiving verteporfin-PDT as a function of time of follow-up. The addition of ranibizumab significantly decreased the need for retreatment with PDT. Reproduced with permission from *Arch Ophthalmol*, 124, 1532–42, 2006.

peated at 3-month intervals if persistent neovascularization was documented. Among the 148 (80.4%) patients with subfoveal CNVs, there was a statistically significant mean increase in visual acuity of 1.14 Snellen lines ($p < 0.01$). The mean number of treatments required was 1.21 with 154 patients (83.7%) requiring only one combination treatment. There was no difference in the response of predominantly classic, minimally classic, or occult CNVs. Forty-six patients (25%) required glaucoma therapy because of transient steroid-induced increased intraocular pressure. (Twelve of these patients had preexisting glaucoma.) Two patients (1%) required surgery for intraocular pressure control. Among phakic eyes, 48.7% experienced cataract progression or underwent cataract extraction during a mean follow-up period of 43 weeks. There were no cases of endophthalmitis. A single-center randomized trial comparing verteporfin-PDT ($n = 30$) to PDT + intravitreal triamcinolone ($n = 31$) found that combined therapy significantly reduced the need for retreatment (1.8 PDT sessions in the combined group vs. 2.9 in the PDT monotherapy cohort; $p = 0.04$).⁶⁶ At the 12-months follow-up, 74% of patients in the combined therapy cohort lost fewer than 15 letters compared with 61% treated with verteporfin alone ($p = 0.78$) despite that the mean visual acuity in the combined therapy cohort was stable but worsened significantly in the verteporfin monotherapy group. Glaucoma occurred in eight (25.8%) patients and cataract progression in eight (32%) of 25 patients. No patient required glaucoma surgery, and there were no cases of endophthalmitis.

Verteporfin-PDT + Ranibizumab. Verteporfin-PDT increases VEGF production in normal human choroidal vasculature.⁶⁷ The majority of patients undergoing verteporfin-PDT demonstrate persistent CNV perfusion with gradual recanalization of the feeder vessels.⁶⁸ This response may contribute to the need for retreatment that is observed in most patients. By binding PDT-induced VEGF-A, ranibizumab might reduce the tendency for CNV regrowth/leakage after treatment. Preclinical studies demonstrate that combined ranibizumab and verteporfin-PDT reduces leakage from laser-induced CNVs more than PDT alone.⁶⁹ In the FOCUS trial, AMD patients with predominantly classic subfoveal CNVs were assigned randomly to verteporfin-PDT plus sham in-

jection ($n = 56$) or verteporfin-PDT plus 0.5 mg ranibizumab injection ($n = 105$).⁷⁰ Sham and true PDT were administered every 3 months as needed. Sham and true injections were done monthly unless verteporfin-PDT was administered, in which case the corresponding ranibizumab dose was skipped. At 24-months follow-up, 91% of patients in the ranibizumab + PDT cohort had <15 letters visual loss vs. 68% in the PDT group ($p = 0.0003$); 24% of patients in the ranibizumab + PDT cohort had 15 or more letters visual improvement vs. 5% in the PDT group ($p = 0.0033$). The percentage of patients receiving repeated verteporfin-PDT was significantly less in the cohort receiving ranibizumab (Fig. 5).

Verteporfin-PDT + Bevacizumab. Dhalla et al. reported a nonrandomized retrospective study in which 24 patients with juxta- ($n = 8$) or subfoveal CNVs were treated with verteporfin-PDT and 1.25 mg bevacizumab.⁷¹ (The two treatments were administered within a 14-days interval.) At month 7, visual acuity stabilized in 83% and improved in 67% of eyes. Mean visual acuity improvement was 2.04 Snellen lines. Fifteen eyes (63%) required only a single combined treatment. No cases of endophthalmitis occurred.

Verteporfin-PDT + Bevacizumab + Dexamethasone. Augustin et al. reported the results of a prospective, noncomparative, interventional case series of 104 patients who received reduced fluence verteporfin-PDT (42 J/cm^2), dexamethasone (800 μg), and bevacizumab (1.5 mg).⁷² Mean follow-up was 40 weeks. The mean increase in visual acuity was 1.8 lines ($p < 0.01$), and the mean decrease in retina thickness was 182 μm ($p < 0.01$). Mean visual acuity at baseline was 20/126, and mean visual acuity at last follow-up was 20/85; 39.3% of patients gained ≥ 3 lines. Only five patients underwent a second triple therapy cycle due to residual CNV activity. Triple therapy was complemented in 18 (17%) patients with an additional intravitreal bevacizumab injection owing to the presence of retinal edema on OCT testing.

Additional studies assessing the effects of combined verteporfin-PDT + Retaane and verteporfin-PDT + Vatalanib (which inhibits VEGFR-1, -2, and -3) are underway. A small retrospective study demonstrated a treatment benefit of pegaptanib + intravitreal tri-

amcinolone + verteporfin-PDT compared with triamcinolone + PDT alone.⁷³

Radiation Therapy + Bevacizumab (Neovista). Phase I data ($n = 26$ patients) indicate that partial vitrectomy and exposure of AMD-associated CNVs to Sr_{90} (24 Gy) using an intraocular delivery system (Epi-Rad₉₀ Ophthalmic System) results in 94% chance of losing <15 letters and a 28% chance of gaining ≥ 15 letters during 1 year of follow-up (Andrew Schachar, MD, personal communication). Results from a second study ($n = 27$) indicate that combined intravitreal bevacizumab and Sr_{90} (24 Gy, Epi-Rad₉₀ Ophthalmic System) results in 100% of patients losing <15 letters and 50% gaining ≥ 15 letters at month 3 after therapy (Andrew Schachar, MD, personal communication). As a result, a prospective, active-controlled, noninferiority design study is planned with patients randomly assigned to 24 Gy (Sr_{90} , 24 Gy, Epi-Rad₉₀ Ophthalmic System) with ranibizumab vs. ranibizumab alone (active control group).

Results of the combination therapy trials mentioned above appear consistent with the notion that combination therapy may provide more definitive treatment for CNVs (i.e., less need for retreatment) than monotherapy and comparable or superior visual results. Better controlled studies are needed to test this hypothesis.

Structure of Future Clinical Trials

Because ranibizumab increases the chance for moderate visual improvement and decreases the chance for at least moderate visual loss regardless of lesion composition, size, or presenting visual acuity, it appears unlikely that a placebo group will be considered an appropriate control for future clinical trials in AMD patients with subfoveal CNVs. Also, because 90% to 95% of patients experience <15 letters visual loss and 25% to 40% of patients experience moderate visual improvement with monthly ranibizumab injections, the endpoint judged as clinically relevant “successful treatment” might have to be reconsidered. Previously, treatments for exudative AMD were judged successful if they reduced the risk of moderate visual loss compared with placebo. Currently, it might be appropriate to consider that among patients with visual acuity worse than 20/50, some degree of visual improvement should be demonstrated for the outcome to be deemed “successful” in a clinically relevant (vs. statistically significant) sense.⁷⁴

Combination therapy trials are likely to dominate the landscape for AMD patients with subfoveal CNVs. If so, then the logistics of designing clinical trials may be more complex than in the past. For example, if visual acuity continues to be the endpoint by which success is judged, then larger numbers of patients may have to be enrolled than in the past because of (1) relatively better visual outcome in the “standard of care” control group (thus requiring a greater number of patients to detect statistically significant differences between treatments or to prove noninferiority of a treatment) and (2) potentially greater numbers of treatment arms in combination therapy trials vs. monotherapy trials. Because patients with better baseline visual acuity tend to have a better final visual acuity with Lucentis treatment,⁷⁴ randomization of patients with good visual acuity to experimental treatment will be challenging. Although patients with lower levels of visual acuity have lower chance of visual loss, testing therapies solely among

this subgroup probably increases the chance of failing to identify a useful treatment benefit unless large numbers of patients are studied.

One approach to this dilemma is to consider redefining the “failure” endpoints in clinical trials. In previous randomized trials, investigators were permitted to reassign patients to proven treatment if they experienced greater than a threshold degree of visual loss. (In the MARINA trial, for example, PDT could be offered to patients randomized to ranibizumab if there was ≥ 20 letters visual loss on two consecutive visits and if the CNV was small, minimally classic or pure occult, with presumed recent disease progression²³). Choosing anatomic endpoints to define failure, rather than psychophysical endpoints, may permit more sensitive identification of disease progression, more timely “rescue” from experimental treatment, and ethical randomization of patients to experimental treatment. There is some evidence that this anatomic approach has merit. In the PIER study, for example, patients were offered PDT at the investigator’s discretion if the lesion converted to predominantly classic choroidal neovascularization. In the PRONTO study, as noted above, an increase of central retinal thickness of at least 100 μm on OCT testing was an indication for ranibizumab treatment. Many clinicians currently assess the need for Lucentis retreatment on the basis of the presence of subretinal fluid evident on OCT data, even if the fluid is not evident clinically. In this regard, ultra-high resolution diagnostic techniques may play an increasingly important role in defining clinical endpoints and may reduce the need for combination therapy trials. For example, AMD patients with excellent visual acuity (e.g., 20/25–20/40) and active subfoveal CNVs might be willing to forgo temporarily intravitreal injection of proved treatment, “A,” for an experimental alternative “B,” which is less invasive or which need not be administered frequently. If an accepted noninvasive imaging technique (e.g., high-resolution OCT⁷⁵) demonstrated worsening while using B (e.g., increasing subretinal fluid and/or increasing photoreceptor degeneration), then the patient could be switched from B to A before there was any change in visual acuity. Such surrogate endpoints might also reduce the duration of clinical trials. Decreasing the number of patients that have to be enrolled in clinical trials and/or decreasing the duration of the trials will, in turn, reduce the development costs of these medications. The net result might be availability of a greater number of treatment alternatives for patients at relatively lower cost.

As mentioned above, in addition to redefining failure, it may be appropriate to reconsider the definition of successful treatment. One criterion, which will endure, is the chance for improved visual acuity compared with standard of care treatment. Another criterion that may emerge is the frequency or nature of the treatment. For example, if treatments A and B produce similar visual outcome, but A requires monthly intravitreal injections and B requires a single intravitreal injection (e.g., gene therapy, caged cell therapy) or a subcutaneous injection, and if both treatments have comparable side effects, then most clinicians and patients will regard B as superior to A.

If large numbers of potential treatments are under study, patient availability may become rate limiting in treatment development. Probably the lessons learned from cancer therapy trials will be relevant in this regard.

Finally, it is not clear what role genetic background will have

Retina Assessment Module (RAM) used in Diabetic Retinopathy

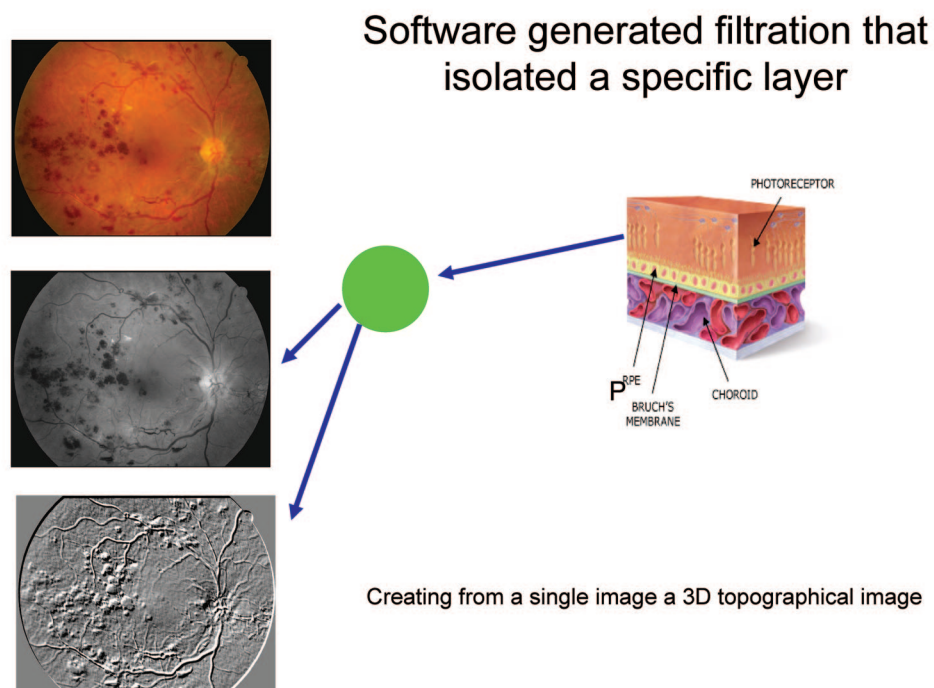


FIGURE 6.

Top left, Color retinal image of patient with diabetic retinopathy. Middle left, Red-free image produced from the color image highlights retinal hemorrhages. Bottom left, Three-dimensional image (green layer) using x axis shift illustrating hemorrhages (shown as elevated).

in selecting patients for clinical trials and in planning prophylactic as well as late-stage treatment for a given patient. As the role of genetic susceptibility is elucidated,^{76–78} different disease pathways probably will be identified. These biochemical pathways provide new opportunities for drug development. They also may identify patients who are likely to respond to a given drug as well as patients who are likely to be resistant to a given treatment.

Role of Improved Diagnostic Imaging

In several randomized clinical trials, patients with subfoveal CNVs typically presented with visual acuity of 20/80 to 20/200.^{22–24} Currently available treatments stabilize vision in ~90% of patients but improve vision in only 25% to 40% of patients. Better noninvasive imaging might help identify patients who can benefit from treatment sooner than visual acuity assessment and clinical examination alone. The result might be better visual outcomes with currently available therapy. In other words, highly sensitive noninvasive imaging may be critical for early detection, timely retreatment, and good visual outcome. Techniques under development include combining OCT and the scanning laser ophthalmoscope (SLO),⁷⁹ high-resolution OCT⁸⁰ with or without combined SLO, as well as the adaptive optics SLO.⁸¹ We have developed a highly sensitive and noninvasive imaging technology that will improve visual outcomes by allowing us to identify patients who will benefit from early detection and timely treatment or retreatment of CNVs. This technology uses high-resolution OCT or combined OCT-SLO.

At the Applied Low Vision Research Laboratory of the Institute of Ophthalmology and Visual Science-New Jersey Medical School, we used a nonmydriatic camera to create a three-dimensional topographic image of the posterior pole from a single-color image. Raw digital color images are composed of three color channels: blue, green, and red (BGR). These channels can be compressed to form three so-called *z*-depth layers or bit depths. Each of these layers can be isolated to highlight ocular structures (Fig. 6). Specifically, the blue channel (with a wavelength of 490 nm) can highlight the innermost layer of the ocular fundus, the nerve fiber layer. The green channel (530 to 550 nm) highlights retinal structures: the optic nerve and the retinal arteries and veins as well as segments of the nerve fiber layer (Fig. 7). The red channel, with the deepest penetrating wavelength of 610 nm, highlights choroidal structures: choroidal vasculature and pigmentary changes associated with nevi, AMD, or choroidal melanoma. The BGR technique can be used to identify drusen under the RPE (Fig. 8).

A color image is typically represented by a bit depth ranging from 8 to 24. A 24-bit image is divided into three groups of 8 bits, with 8 bits for each BGR channel. By shifting the pixels in any one of these channels to the left or the right along the *x* axis, it is possible to create a positive or negative stereo image with a vividly dimensional elevation or depression. Each color channel can be divided further into additional layers. The greater the bit depth (*z* axis) of an image, the higher will be its resolution.

In summary, we have overcome an important limitation of retinal imaging by developing a technique that confers dimen-

Retina Assessment Module (RAM) in Digital Imaging of AMD

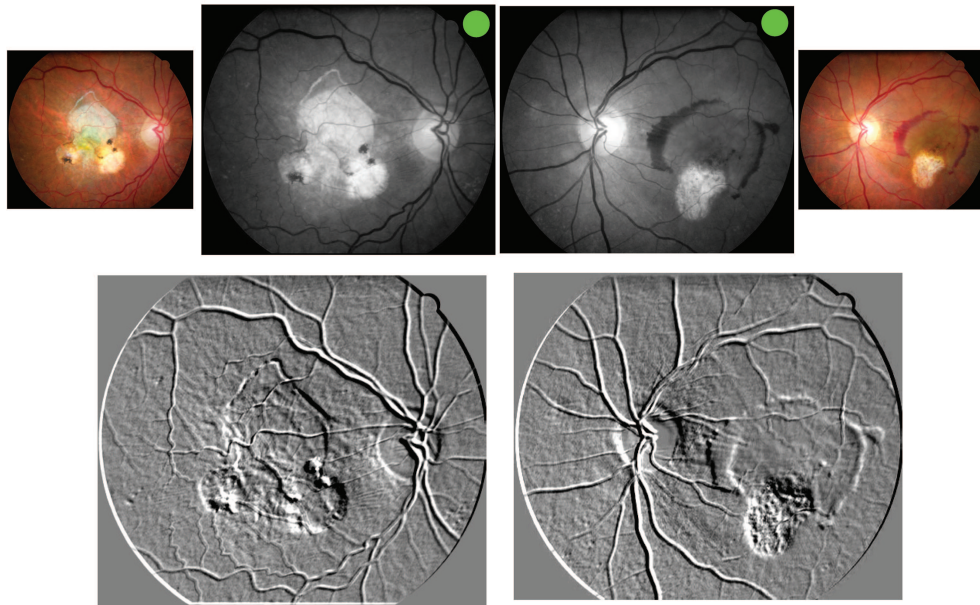


FIGURE 7.

Top left and right, Nonmydriatic color image (wet AMD) of right and left eyes captured using a Canon CR-DGi 45° with a resolution of 8.2 megapixels. Top center-left and top center-right, Red-free images (green, 550-nm software-driven filters produced from color images) are shown. Bottom left and right, Three-dimensional images produced from the red-free layer using x axis shift. Note the excavation in the areas of scarring and the area of elevation associated with thin subretinal hemorrhage in the left eye.

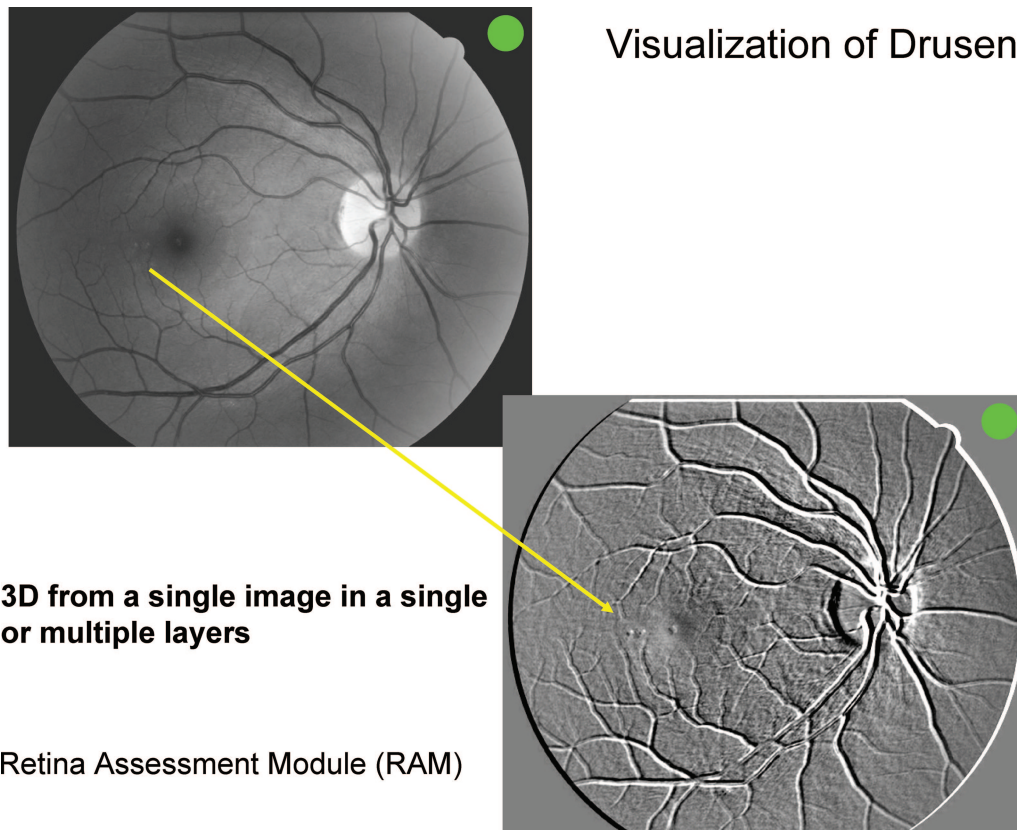


FIGURE 8.

Top left, Red-free image of patient with small parafoveal drusen. Bottom right, Three-dimensional image in red channel highlights well the parafoveal drusen that are not easy to discern in the red-free image. Thus, this technique highlights well the distortions in the flat architecture of the RPE-Bruch's membrane-choriocapillaris complex.

sionality to a single digital image and creates three-dimensional color images of ocular structures and abnormalities.

CONCLUSIONS

Defining the cell biology of CNV formation and geographic atrophy will lead to the identification of different biochemical pathways that are the target of AMD treatment. Many treatments and treatment combinations are under study for AMD, but all work through a finite number of pathways.

Currently, the most effective proved therapy for AMD-associated CNVs is administered by repeated intravitreal injection. Improved drug delivery will enhance patient satisfaction and possibly will enhance the effectiveness and reduce the risk of current pharmacotherapy for AMD-associated CNVs. Combination therapy (e.g., verteporfin-PDT + ranibizumab) appears to reduce the risk and enhance the effectiveness of CNV treatment compared with monotherapy with currently available agents. Combination therapy is likely to be an area of intense investigation during the next few years.

Improved diagnostic imaging may lead to better visual outcomes with existing therapeutic modalities. Improved noninvasive imaging also may alter favorably the design of future clinical trials for AMD-associated CNVs and thus reduce the cost and increase the diversity of sight-saving treatments.

Received April 12, 2007; accepted May 5, 2007.

REFERENCES

- Klein R, Klein BE, Jensen SC, Meuer SM. The five-year incidence and progression of age-related maculopathy: the Beaver Dam Eye Study. *Ophthalmology* 1997;104:7–21.
- Zarbin MA. Current concepts in the pathogenesis of age-related macular degeneration. *Arch Ophthalmol* 2004;122:598–614.
- Klein R, Klein BE, Linton KL. Prevalence of age-related maculopathy. The Beaver Dam Eye Study. *Ophthalmology* 1992;99:933–43.
- Vingerling JR, Dielemans I, Hofman A, Grobbee DE, Hijmering M, Kramer CF, de Jong PT. The prevalence of age-related maculopathy in the Rotterdam Study. *Ophthalmology* 1995;102:205–10.
- Evans J, Wormald R. Is the incidence of registrable age-related macular degeneration increasing. *Br J Ophthalmol* 1996;80:9–14.
- A randomized, placebo-controlled, clinical trial of high-dose supplementation with vitamins C and E, beta carotene, and zinc for age-related macular degeneration and vision loss: AREDS report no. 8. *Arch Ophthalmol* 2001;119:1417–36.
- Argon laser photocoagulation for neovascular maculopathy. Five-year results from randomized clinical trials. Macular Photocoagulation Study Group. *Arch Ophthalmol* 1991;109:1109–14.
- Freund KB, Yannuzzi LA, Sorenson JA. Age-related macular degeneration and choroidal neovascularization. *Am J Ophthalmol* 1993;115:786–91.
- Moisseiev J, Alhalel A, Masuri R, Treister G. The impact of the macular photocoagulation study results on the treatment of exudative age-related macular degeneration. *Arch Ophthalmol* 1995;113:185–9.
- Schmidt-Erfurth U, Hasan T. Mechanisms of action of photodynamic therapy with verteporfin for the treatment of age-related macular degeneration. *Surv Ophthalmol* 2000;45:195–214.
- Fingar VH. Vascular effects of photodynamic therapy. *J Clin Laser Med Surg* 1996;14:323–8.
- Paskowitz DM, Nune G, Yasumura D, Yang H, Bhisitkul RB, Sharma S, Matthes MT, Zarbin MA, Lavail MM, Duncan JL. BDNF reduces the retinal toxicity of verteporfin photodynamic therapy. *Invest Ophthalmol Vis Sci* 2004;45:4190–6.
- Paskowitz DM, Donohue-Rolfe KM, Yang H, Yasumura D, Matthes MT, Hosseini K, Graybeal CM, Nune G, Zarbin MA, Lavail MM, Duncan JL. Neurotrophic factors minimize the retinal toxicity of verteporfin photodynamic therapy. *Invest Ophthalmol Vis Sci* 2007;48:430–7.
- Bressler NM, Arnold J, Benchaboune M, Blumenkranz MS, Fish GE, Gragoudas ES, Lewis H, Schmidt-Erfurth U, Slakter JS, Bressler SB, Manos K, Hao Y, Hayes L, Koester J, Reaves A, Strong HA. Verteporfin therapy of subfoveal choroidal neovascularization in patients with age-related macular degeneration: additional information regarding baseline lesion composition's impact on vision outcomes-TAP report No. 3. *Arch Ophthalmol* 2002;120:1443–54.
- Bressler NM, Bressler SB, Haynes LA, Hao Y, Kaiser PK, Miller JW, Naor J, Potter MJ, Pournaras CJ, Reaves A, Rosenfeld PJ, Schmidt-Erfurth U, Slakter JS, Strong A, Vannier S. Verteporfin therapy for subfoveal choroidal neovascularization in age-related macular degeneration: four-year results of an open-label extension of 2 randomized clinical trials: TAP Report No. 7. *Arch Ophthalmol* 2005;123:1283–5.
- Ferrara N, Gerber HP, LeCouter J. The biology of VEGF and its receptors. *Nat Med* 2003;9:669–76.
- Robinson CJ, Stringer SE. The splice variants of vascular endothelial growth factor (VEGF) and their receptors. *J Cell Sci* 2001;114:853–65.
- Ruckman J, Green LS, Beeson J, Waugh S, Gillette WL, Henninger DD, Claesson-Welsh L, Janjic N. 2'-Fluoropyrimidine RNA-based aptamers to the 165-amino acid form of vascular endothelial growth factor (VEGF165). Inhibition of receptor binding and VEGF-induced vascular permeability through interactions requiring the exon 7-encoded domain. *J Biol Chem* 1998;273:20556–67.
- Houck KA, Leung DW, Rowland AM, Winer J, Ferrara N. Dual regulation of vascular endothelial growth factor bioavailability by genetic and proteolytic mechanisms. *J Biol Chem* 1992;267:26031–7.
- Keyt BA, Berleau LT, Nguyen HV, Chen H, Heinsohn H, Vandlen R, Ferrara N. The carboxyl-terminal domain (111–165) of vascular endothelial growth factor is critical for its mitogenic potency. *J Biol Chem* 1996;271:7788–95.
- Lee S, Jilani SM, Nikolova GV, Carpizo D, Iruela-Arispe ML. Processing of VEGF-A by matrix metalloproteinases regulates bioavailability and vascular patterning in tumors. *J Cell Biol* 2005;169:681–91.
- Gragoudas ES, Adamis AP, Cunningham ET Jr, Feinsod M, Guyer DR. Pegaptanib for neovascular age-related macular degeneration. *N Engl J Med* 2004;351:2805–16.
- Rosenfeld PJ, Brown DM, Heier JS, Boyer DS, Kaiser PK, Chung CY, Kim RY. Ranibizumab for neovascular age-related macular degeneration. *N Engl J Med* 2006;355:1419–31.
- Brown DM, Kaiser PK, Michels M, Soubrane G, Heier JS, Kim RY, Sy JP, Schneider S. Ranibizumab versus verteporfin for neovascular age-related macular degeneration. *N Engl J Med* 2006;355:1432–44.
- Fung AE, Lalwani GA, Rosenfeld PJ, Dubovy SR, Michels S, Feuer WJ, Puliafito CA, Davis JL, Flynn HW Jr, Esquiabro M. An optical coherence tomography-guided, variable dosing regimen with intravitreal ranibizumab (Lucentis) for neovascular age-related macular degeneration. *Am J Ophthalmol* 2007;143:566–83.
- Collaborative overview of randomised trials of antiplatelet therapy. I. Prevention of death, myocardial infarction, and stroke by prolonged

- antiplatelet therapy in various categories of patients. Antiplatelet Trialists' Collaboration. *BMJ* 1994;308:81–106.
27. Steinbrook R. The price of sight—ranibizumab, bevacizumab, and the treatment of macular degeneration. *N Engl J Med* 2006;355:1409–12.
 28. Avery RL, Pearlman J, Pieramici DJ, Rabena MD, Castellarin AA, Nasir MA, Giust MJ, Wendel R, Patel A. Intravitreal bevacizumab (Avastin) in the treatment of proliferative diabetic retinopathy. *Ophthalmology* 2006;113:1695; e1–e15.
 29. Rosenfeld PJ, Moshfeghi AA, Puliafito CA. Optical coherence tomography findings after an intravitreal injection of bevacizumab (avastin) for neovascular age-related macular degeneration. *Ophthalmic Surg Lasers Imaging* 2005;36:331–5.
 30. Rich RM, Rosenfeld PJ, Puliafito CA, Dubovy SR, Davis JL, Flynn HW Jr, Gonzalez S, Feuer WJ, Lin RC, Lalwani GA, Nguyen JK, Kumar G. Short-term safety and efficacy of intravitreal bevacizumab (Avastin) for neovascular age-related macular degeneration. *Retina* 2006;26:495–511.
 31. Avery RL, Pieramici DJ, Rabena MD, Castellarin AA, Nasir MA, Giust MJ. Intravitreal bevacizumab (Avastin) for neovascular age-related macular degeneration. *Ophthalmology* 2006;113:363–72; e5.
 32. Spaide RF, Laud K, Fine HF, Klancnik JM Jr, Meyerle CB, Yannuzzi LA, Sorenson J, Slakter J, Fisher YL, Cooney MJ. Intravitreal bevacizumab treatment of choroidal neovascularization secondary to age-related macular degeneration. *Retina* 2006;26:383–90.
 33. Costa RA, Jorge R, Calucci D, Cardillo JA, Melo LA Jr, Scott IU. Intravitreal bevacizumab for choroidal neovascularization caused by AMD (IBeNA Study): results of a phase 1 dose-escalation study. *Invest Ophthalmol Vis Sci* 2006;47:4569–78.
 34. D'Amico DJ, Goldberg MF, Hudson H, Jerdan JA, Krueger DS, Luna SP, Robertson SM, Russell S, Singerman L, Slakter JS, Yannuzzi L, Zilliox P. Anecortave acetate as monotherapy for treatment of subfoveal neovascularization in age-related macular degeneration: twelve-month clinical outcomes. *Ophthalmology* 2003;110:2372–83.
 35. Schmidt-Erfurth U, Michels S, Michels R, Aue A. Anecortave acetate for the treatment of subfoveal choroidal neovascularization secondary to age-related macular degeneration. *Eur J Ophthalmol* 2005;15:482–5.
 36. Slakter JS, Bochow TW, D'Amico DJ, Marks B, Jerdan J, Sullivan EK, Robertson SM, Sullins G, Zilliox P. Anecortave acetate (15 milligrams) versus photodynamic therapy for treatment of subfoveal neovascularization in age-related macular degeneration. *Ophthalmology* 2006;113:3–13.
 37. Luttun A, Tjwa M, Carmeliet P. Placental growth factor (PlGF) and its receptor Flt-1 (VEGFR-1): novel therapeutic targets for angiogenic disorders. *Ann N Y Acad Sci* 2002;979:80–93.
 38. Dvorak HF. Vascular permeability factor/vascular endothelial growth factor: a critical cytokine in tumor angiogenesis and a potential target for diagnosis and therapy. *J Clin Oncol* 2002;20:4368–80.
 39. Nguyen QD, Shah SM, Hafiz G, Quinlan E, Sung J, Chu K, Cedarbaum JM, Campochiaro PA. A phase I trial of an IV-administered vascular endothelial growth factor trap for treatment in patients with choroidal neovascularization due to age-related macular degeneration. *Ophthalmology* 2006;113:1522; e1–e14.
 40. Reich SJ, Fosnot J, Kuroki A, Tang W, Yang X, Maguire AM, Bennett J, Tolentino MJ. Small interfering RNA (siRNA) targeting VEGF effectively inhibits ocular neovascularization in a mouse model. *Mol Vis* 2003;9:210–16.
 41. Shen J, Samul R, Silva RL, Akiyama H, Liu H, Saishin Y, Hackett SF, Zinnen S, Kossen K, Fosnaugh K, Vargeese C, Gomez A, Bouhana K, Aitchison R, Pavco P, Campochiaro PA. Suppression of ocular neovascularization with siRNA targeting VEGF receptor 1. *Gene Ther* 2006;13:225–34.
 42. Saishin Y, Silva RL, Kachi S, Aslam S, Gong YY, Lai H, Carrion M, Harris B, Hamilton M, Wei L, Campochiaro PA. Periocular gene transfer of pigment epithelium-derived factor inhibits choroidal neovascularization in a human-sized eye. *Hum Gene Ther* 2005;16:473–8.
 43. Jaffe GJ, Martin D, Callanan D, Pearson PA, Levy B, Comstock T. Fluocinolone acetonide implant (Retisert) for noninfectious posterior uveitis: thirty-four-week results of a multicenter randomized clinical study. *Ophthalmology* 2006;113:1020–7.
 44. Sieving PA, Caruso RC, Tao W, Coleman HR, Thompson DJ, Fullmer KR, Bush RA. Ciliary neurotrophic factor (CNTF) for human retinal degeneration: phase I trial of CNTF delivered by encapsulated cell intraocular implants. *Proc Natl Acad Sci USA* 2006;103:3896–901.
 45. Klement G, Baruchel S, Rak J, Man S, Clark K, Hicklin DJ, Bohlen P, Kerbel RS. Continuous low-dose therapy with vinblastine and VEGF receptor-2 antibody induces sustained tumor regression without overt toxicity. *J Clin Invest* 2000;105:R15–R24.
 46. Lee CG, Heijn M, di Tomaso E, Griffon-Etienne G, Ancukiewicz M, Koike C, Park KR, Ferrara N, Jain RK, Suit HD, Boucher Y. Anti-vascular endothelial growth factor treatment augments tumor radiation response under normoxic or hypoxic conditions. *Cancer Res* 2000;60:5565–70.
 47. Benjamin LE, Hemo I, Keshet E. A plasticity window for blood vessel remodelling is defined by pericyte coverage of the preformed endothelial network and is regulated by PDGF-B and VEGF. *Development* 1998;125:1591–8.
 48. Benjamin LE, Golijanin D, Itin A, Pode D, Keshet E. Selective ablation of immature blood vessels in established human tumors follows vascular endothelial growth factor withdrawal. *J Clin Invest* 1999;103:159–65.
 49. Hellstrom M, Kalen M, Lindahl P, Abramsson A, Betsholtz C. Role of PDGF-B and PDGFR-beta in recruitment of vascular smooth muscle cells and pericytes during embryonic blood vessel formation in the mouse. *Development* 1999;126:3047–55.
 50. Jo N, Mailhos C, Ju M, Cheung E, Bradley J, Nishijima K, Robinson GS, Adamis AP, Shima DT. Inhibition of platelet-derived growth factor B signaling enhances the efficacy of anti-vascular endothelial growth factor therapy in multiple models of ocular neovascularization. *Am J Pathol* 2006;168:2036–53.
 51. Zarbin M. Should corticosteroids be considered as part of the standard care with photodynamic therapy. *Arch Ophthalmol* 2006;124:563–71.
 52. Folkman J, Ingber DE. Angiostatic steroids. Method of discovery and mechanism of action. *Ann Surg* 1987;206:374–83.
 53. Proia AD, Hirakata A, McInnes JS, Scroggs MW, Parikh I. The effect of angiostatic steroids and beta-cyclodextrin tetradecasulfate on corneal neovascularization in the rat. *Exp Eye Res* 1993;57:693–8.
 54. Oh H, Takagi H, Takagi C, Suzuma K, Otani A, Ishida K, Matsumura M, Ogura Y, Honda Y. The potential angiogenic role of macrophages in the formation of choroidal neovascular membranes. *Invest Ophthalmol Vis Sci* 1999;40:1891–8.
 55. Wang YS, Friedrichs U, Eichler W, Hoffmann S, Wiedemann P. Inhibitory effects of triamcinolone acetonide on bFGF-induced migration and tube formation in choroidal microvascular endothelial cells. *Graefes Arch Clin Exp Ophthalmol* 2002;240:42–8.
 56. Matsuda S, Gomi F, Oshima Y, Tohyama M, Tano Y. Vascular endothelial growth factor reduced and connective tissue growth factor induced by triamcinolone in ARPE19 cells under oxidative stress. *Invest Ophthalmol Vis Sci* 2005;46:1062–8.
 57. Penfold PL, Wen L, Madigan MC, Gillies MC, King NJ, Provis JM.

- Triamcinolone acetonide modulates permeability and intercellular adhesion molecule-1 (ICAM-1) expression of the ECV304 cell line: implications for macular degeneration. *Clin Exp Immunol* 2000; 121:458–65.
58. Wilson CA, Berkowitz BA, Sato Y, Ando N, Handa JT, de Juan E Jr. Treatment with intravitreal steroid reduces blood-retinal barrier breakdown due to retinal photocoagulation. *Arch Ophthalmol* 1992; 110:1155–9.
 59. Nauck M, Karakiulakis G, Perruchoud AP, Papakonstantinou E, Roth M. Corticosteroids inhibit the expression of the vascular endothelial growth factor gene in human vascular smooth muscle cells. *Eur J Pharmacol* 1998;341:309–15.
 60. Penfold PL, Wong JG, Gyory J, Billson FA. Effects of triamcinolone acetonide on microglial morphology and quantitative expression of MHC-II in exudative age-related macular degeneration. *Clin Experiment Ophthalmol* 2001;29:188–92.
 61. Augustin AJ, Schmidt-Erfurth U. Verteporfin therapy combined with intravitreal triamcinolone in all types of choroidal neovascularization due to age-related macular degeneration. *Ophthalmology* 2006;113:14–22.
 62. Ruiz-Moreno JM, Montero JA, Barile S, Zarbin MA. Photodynamic therapy and high-dose intravitreal triamcinolone to treat exudative age-related macular degeneration: 1-year outcome. *Retina* 2006;26: 602–12.
 63. Spaide RF, Sorenson J, Maranan L. Photodynamic therapy with verteporfin combined with intravitreal injection of triamcinolone acetonide for choroidal neovascularization. *Ophthalmology* 2005; 112:301–4.
 64. Rechtman E, Danis RP, Pratt LM, Harris A. Intravitreal triamcinolone with photodynamic therapy for subfoveal choroidal neovascularisation in age related macular degeneration. *Br J Ophthalmol* 2004;88:344–7.
 65. Augustin AJ, Schmidt-Erfurth U. Verteporfin and intravitreal triamcinolone acetonide combination therapy for occult choroidal neovascularization in age-related macular degeneration. *Am J Ophthalmol* 2006;141:638–45.
 66. Arias L, Garcia-Arumi J, Ramon JM, Badia M, Rubio M, Pujol O. Photodynamic therapy with intravitreal triamcinolone in predominantly classic choroidal neovascularization: one-year results of a randomized study. *Ophthalmology* 2006;113:2243–50.
 67. Schmidt-Erfurth U, Schlotzer-Schrehard U, Cursiefen C, Michels S, Beckendorf A, Naumann GO. Influence of photodynamic therapy on expression of vascular endothelial growth factor (VEGF), VEGF receptor 3, and pigment epithelium-derived factor. *Invest Ophthalmol Vis Sci* 2003;44:4473–80.
 68. Schmidt-Erfurth U, Michels S, Barbazetto I, Laqua H. Photodynamic effects on choroidal neovascularization and physiological choroid. *Invest Ophthalmol Vis Sci* 2002;43:830–41.
 69. Husain D, Kim I, Gauthier D, Lane AM, Tsilimbaris MK, Ezra E, Connolly EJ, Michaud N, Gragoudas ES, O'Neill CA, Beyer JC, Miller JW. Safety and efficacy of intravitreal injection of ranibizumab in combination with verteporfin PDT on experimental choroidal neovascularization in the monkey. *Arch Ophthalmol* 2005;123: 509–16.
 70. Heier JS, Boyer DS, Ciulla TA, Ferrone PJ, Jumper JM, Gentile RC, Kotlovker D, Chung CY, Kim RY. Ranibizumab combined with verteporfin photodynamic therapy in neovascular age-related macular degeneration: year 1 results of the FOCUS Study. *Arch Ophthalmol* 2006;124:1532–42.
 71. Dhalla MS, Shah GK, Blinder KJ, Ryan EH Jr, Mitra RA, Tewari A. Combined photodynamic therapy with verteporfin and intravitreal bevacizumab for choroidal neovascularization in age-related macular degeneration. *Retina* 2006;26:988–93.
 72. Augustin AJ, Puls S, Offermann I. Triple therapy for choroidal neovascularization due to age-related macular degeneration: verteporfin PDT, bevacizumab, and dexamethasone. *Retina* 2007;27:133–40.
 73. Liggett PE, Colina J, Chaudhry NA, Tom D, Haffner G. Triple therapy of intravitreal triamcinolone, photodynamic therapy, and pegaptanib sodium for choroidal neovascularization. *Am J Ophthalmol* 2006;142:1072–4.
 74. Boyer DS, Antoszyk AN, Awh CC, Bhisitkul RB, Shapiro H, Acharya NR. Subgroup analysis of the MARINA study of ranibizumab in neovascular age-related macular degeneration. *Ophthalmology* 2007; 114:246–52.
 75. Alam S, Zawadzki RJ, Choi S, Gerth C, Park SS, Morse L, Werner JS. Clinical application of rapid serial Fourier-domain optical coherence tomography for macular imaging. *Ophthalmology* 2006;113: 1425–31.
 76. Edwards AO, Ritter R III, Abel KJ, Manning A, Panhuysen C, Farrer LA. Complement factor H polymorphism and age-related macular degeneration. *Science* 2005;308:421–4.
 77. Gold B, Merriam JE, Zernant J, Hancox LS, Taiber AJ, Gehrs K, Cramer K, Neel J, Bergeron J, Barile GR, Smith RT, Hageman GS, Dean M, Allikmets R. Variation in factor B (BF) and complement component 2 (C2) genes is associated with age-related macular degeneration. *Nat Genet* 2006;38:458–62.
 78. Hageman GS, Anderson DH, Johnson LV, Hancox LS, Taiber AJ, Hardisty LI, Hageman JL, Stockman HA, Borchardt JD, Gehrs KM, Smith RJ, Silvestri G, Russell SR, Klaver CC, Barbazetto I, Chang S, Yannuzzi LA, Barile GR, Merriam JC, Smith RT, Olsh AK, Bergeron J, Zernant J, Merriam JE, Gold B, Dean M, Allikmets R. A common haplotype in the complement regulatory gene factor H (HF1/CFH) predisposes individuals to age-related macular degeneration. *Proc Natl Acad Sci USA* 2005;102:7227–32.
 79. Podoleanu AG. Combining SLO and OCT technology. *Bull Soc Belge Ophthalmol* 2006;133–51.
 80. Drexler W, Sattmann H, Hermann B, Ko TH, Stur M, Unterhuber A, Scholda C, Findl O, Wirtitsch M, Fujimoto JG, Fercher AF. Enhanced visualization of macular pathology with the use of ultra-high-resolution optical coherence tomography. *Arch Ophthalmol* 2003;121:695–706.
 81. Wolfing JI, Chung M, Carroll J, Roorda A, Williams DR. High-resolution retinal imaging of cone-rod dystrophy. *Ophthalmology* 2006;113:1019; e1.

Marco Zarbin

Institute of Ophthalmology and Visual Science

New Jersey Medical School

90 Bergen St.

Room 6156

Newark, NJ 07103

e-mail: zarbin@umdnj.edu